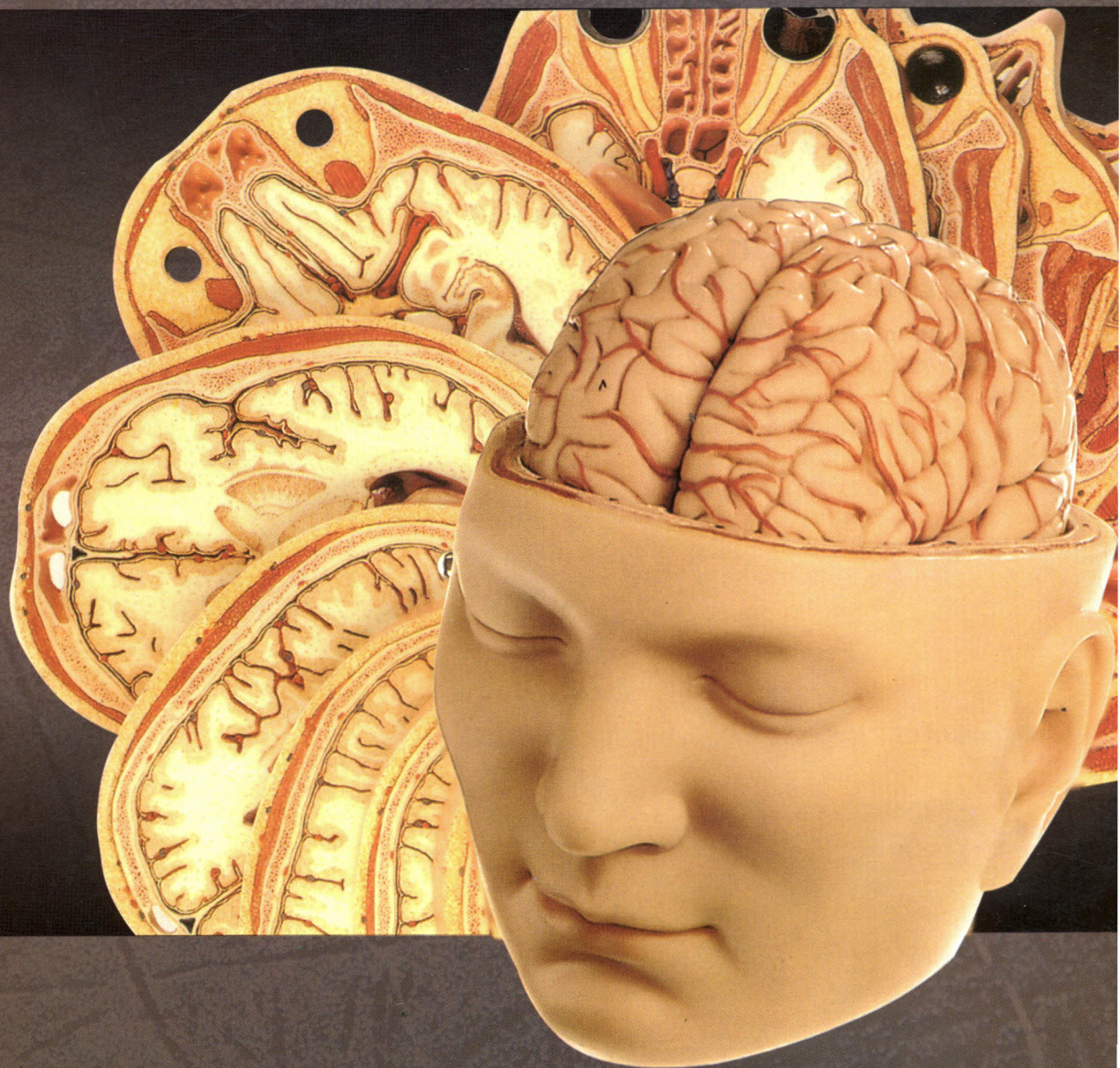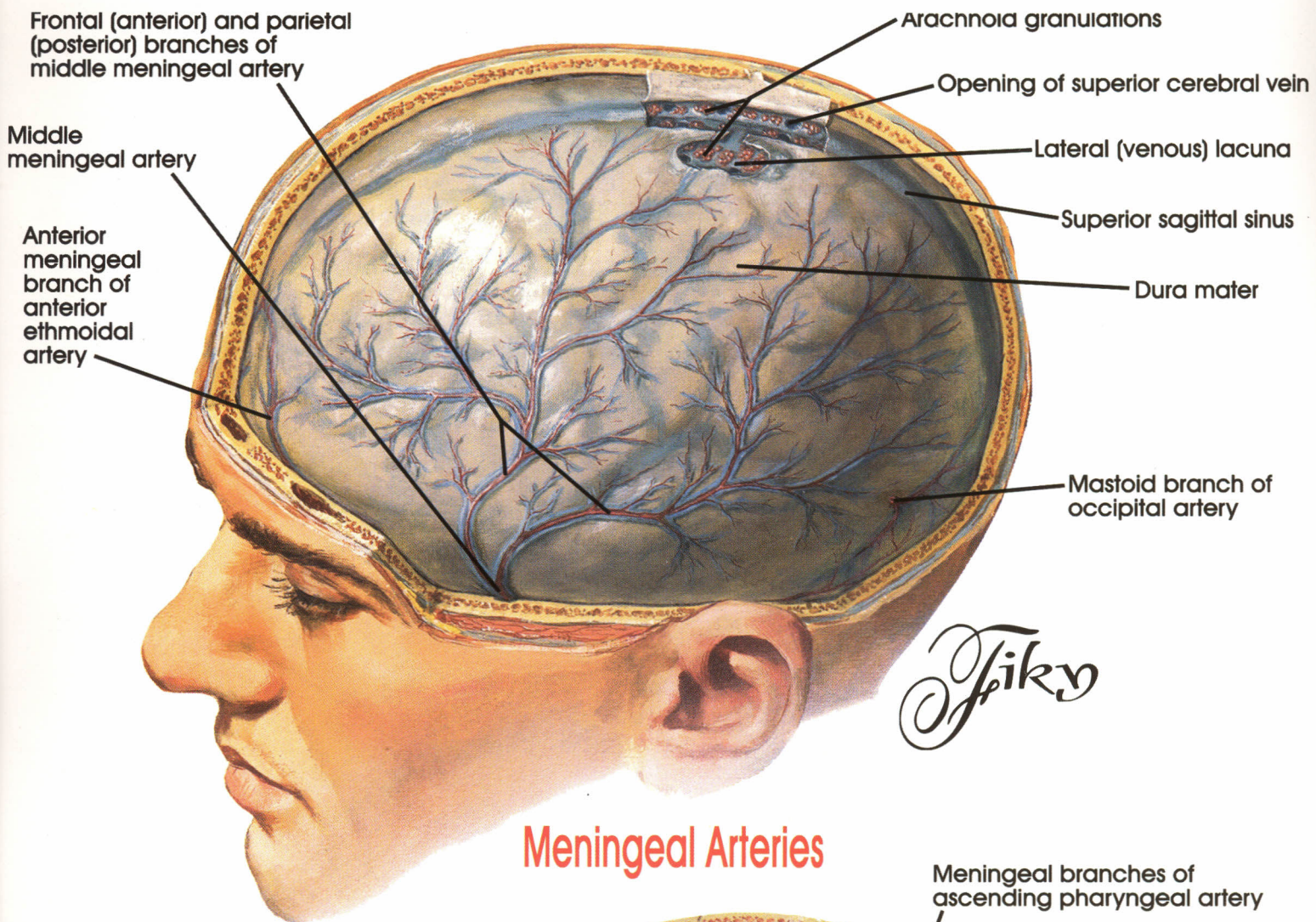


El-Fiky's

MINI ATLAS OF
ANATOMY
PART VI
NEURO ANATOMY

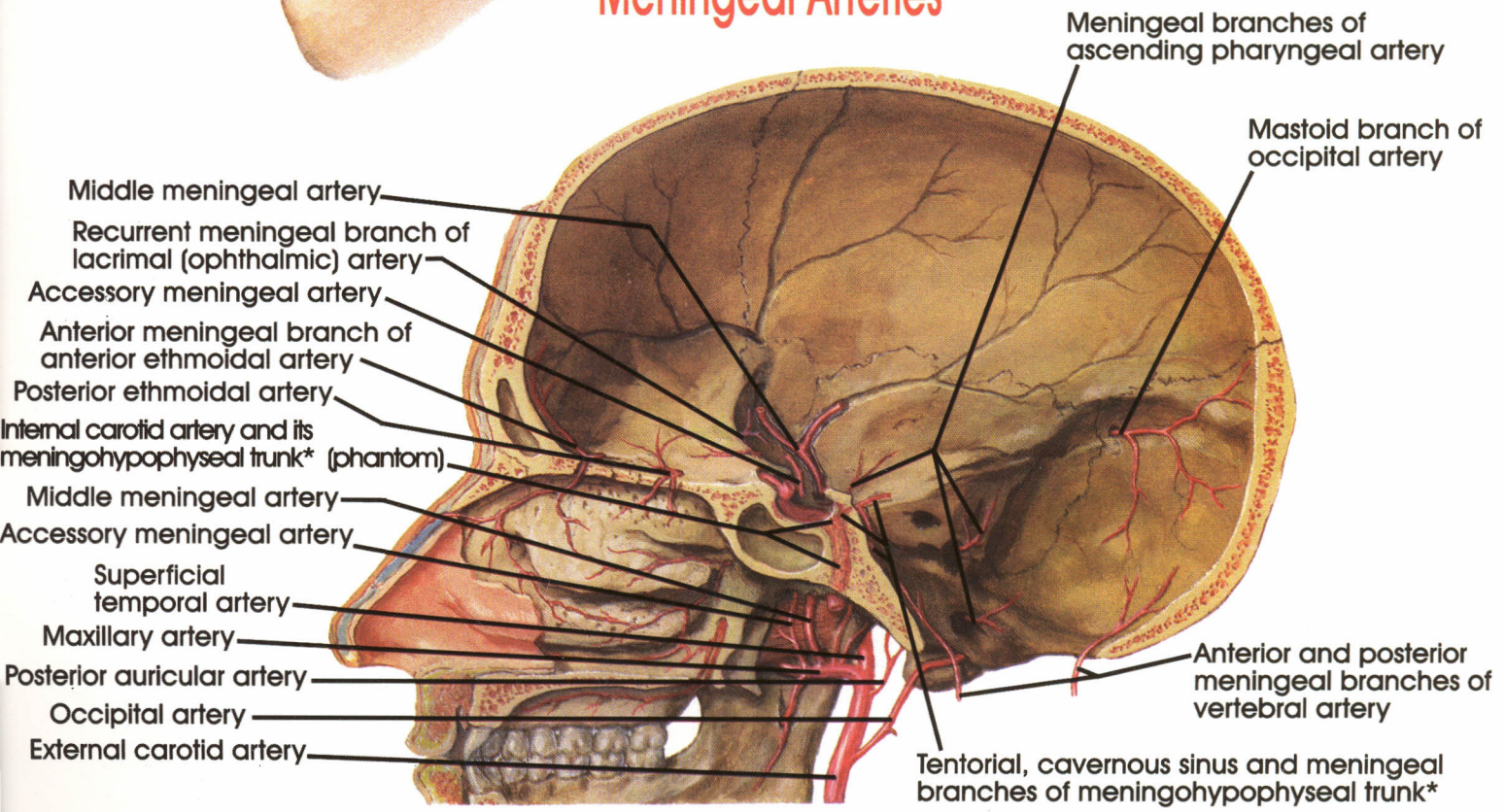


DR. MOHAMED EL-FIKY
Assist.Prof. of Anatomy & Embryology
Faculty of Medicine Menoufia university



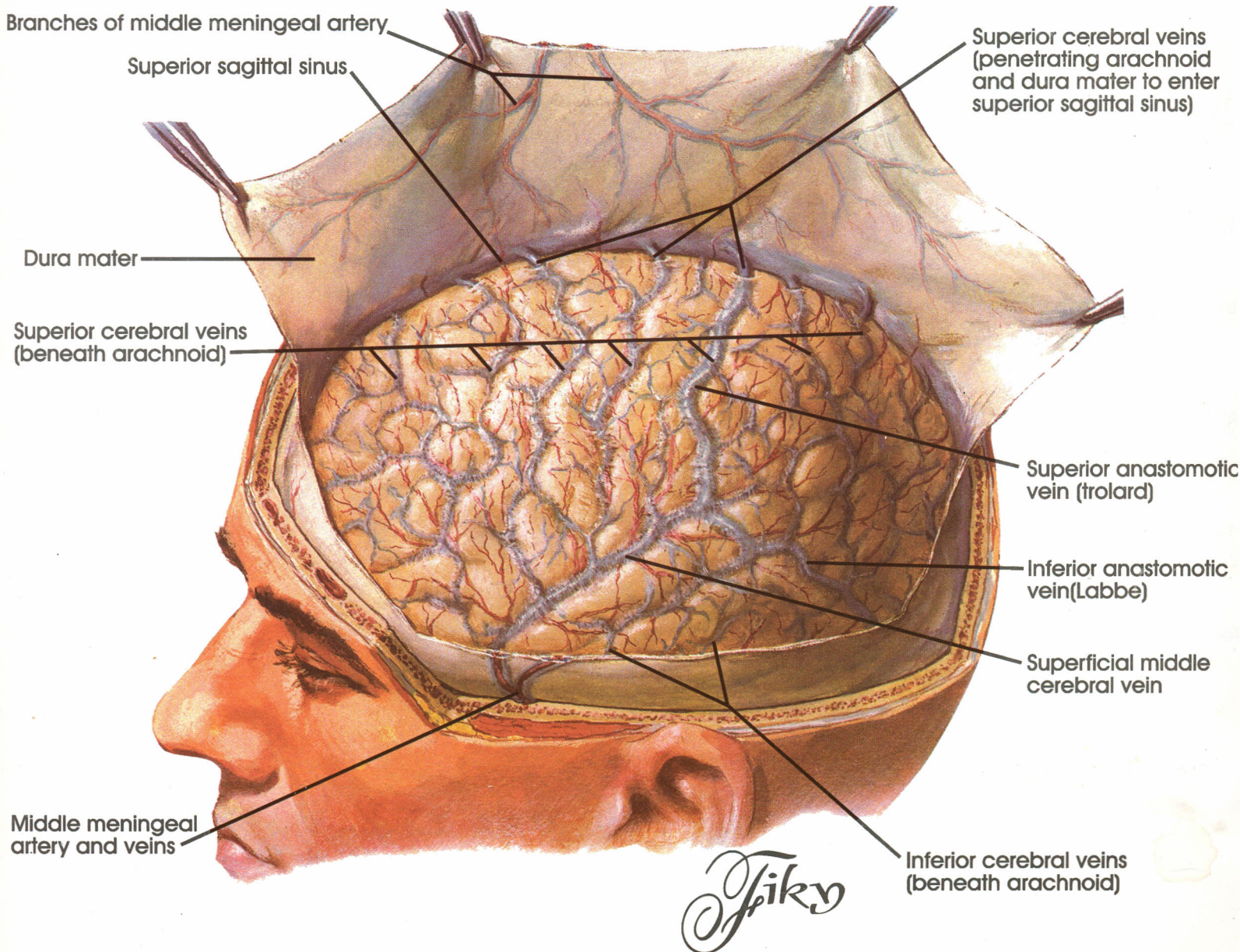
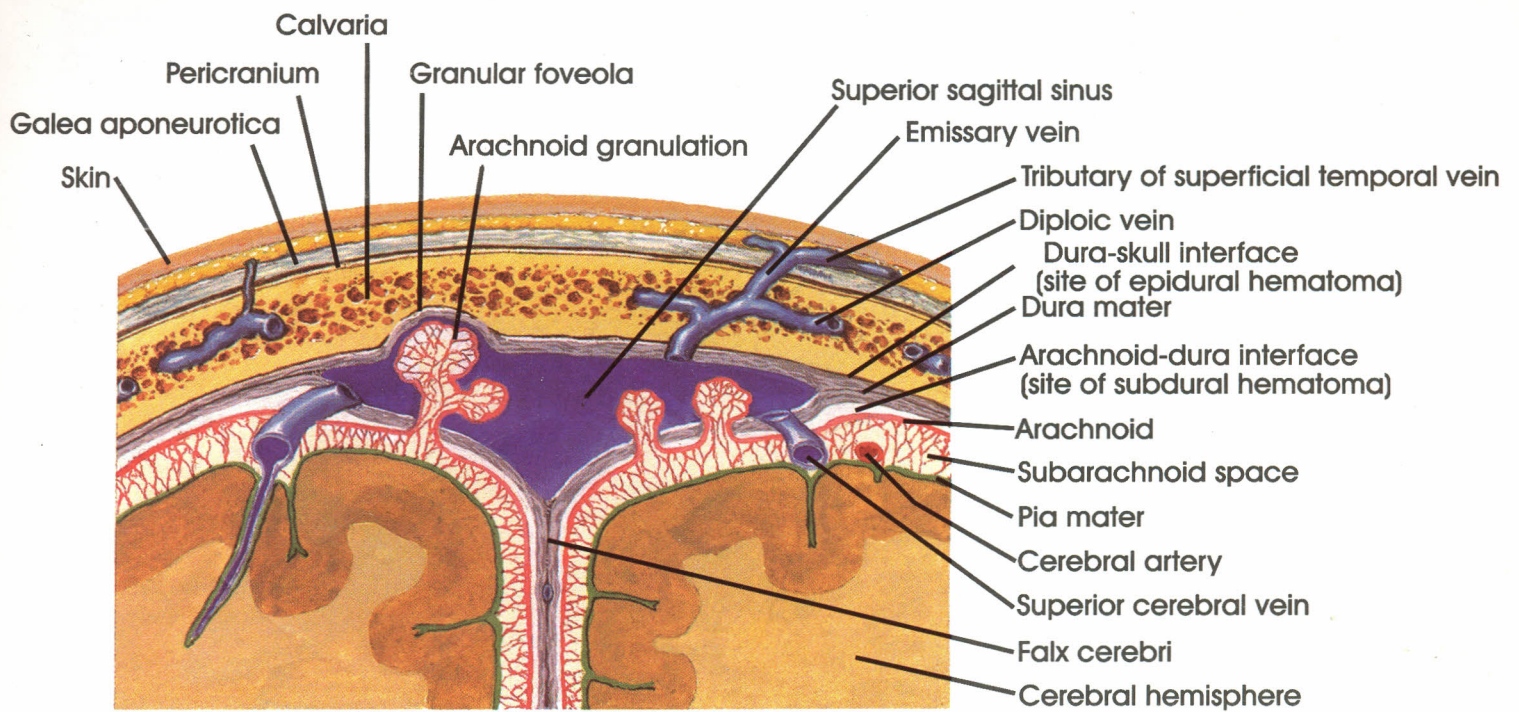
Spiky

Meningeal Arteries

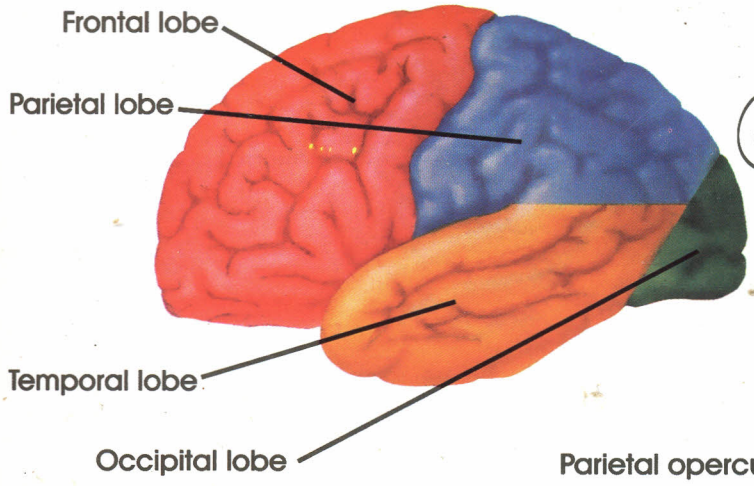
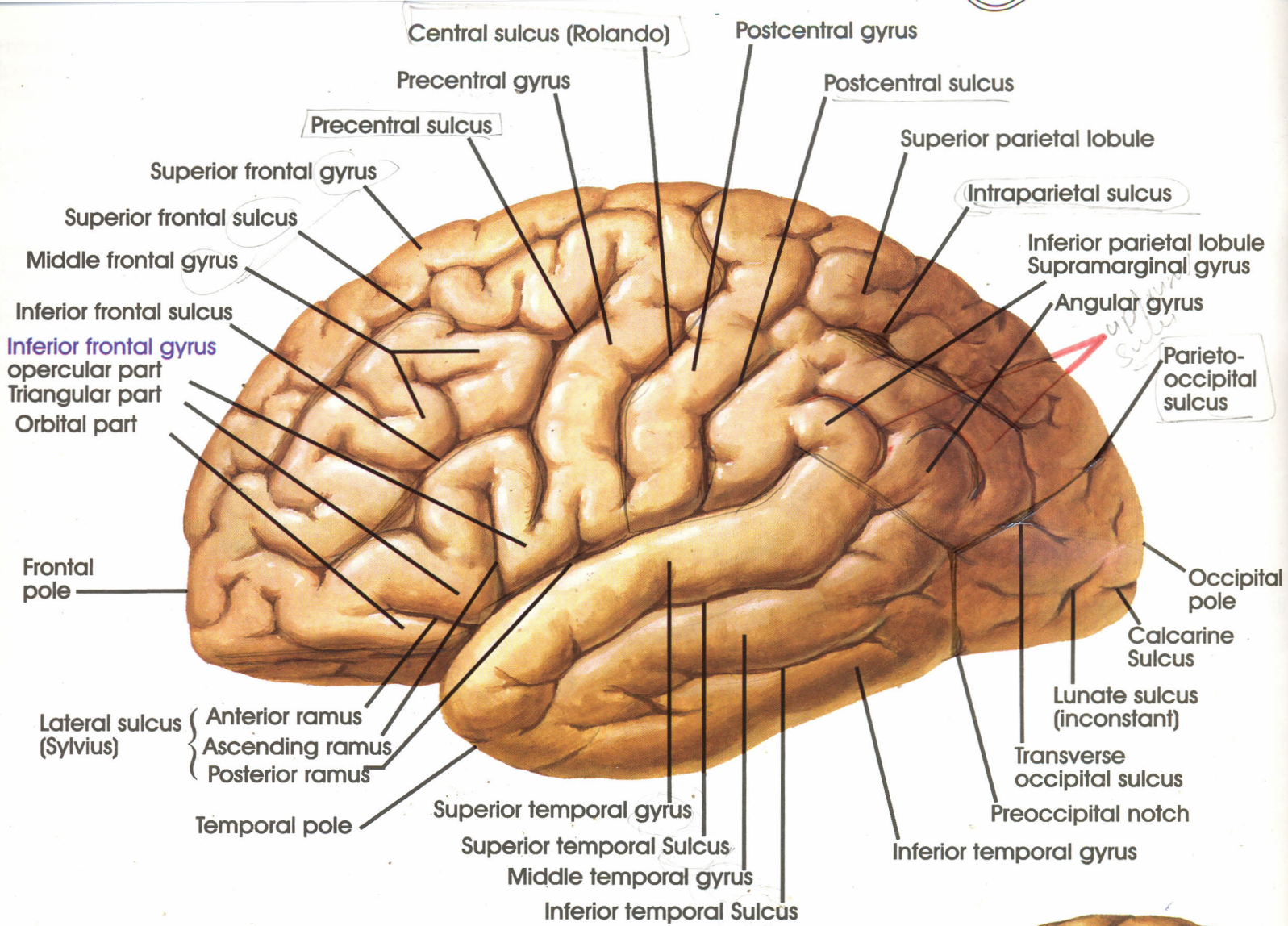


*Variant : most commonly, these branches are directly from internal carotid artery

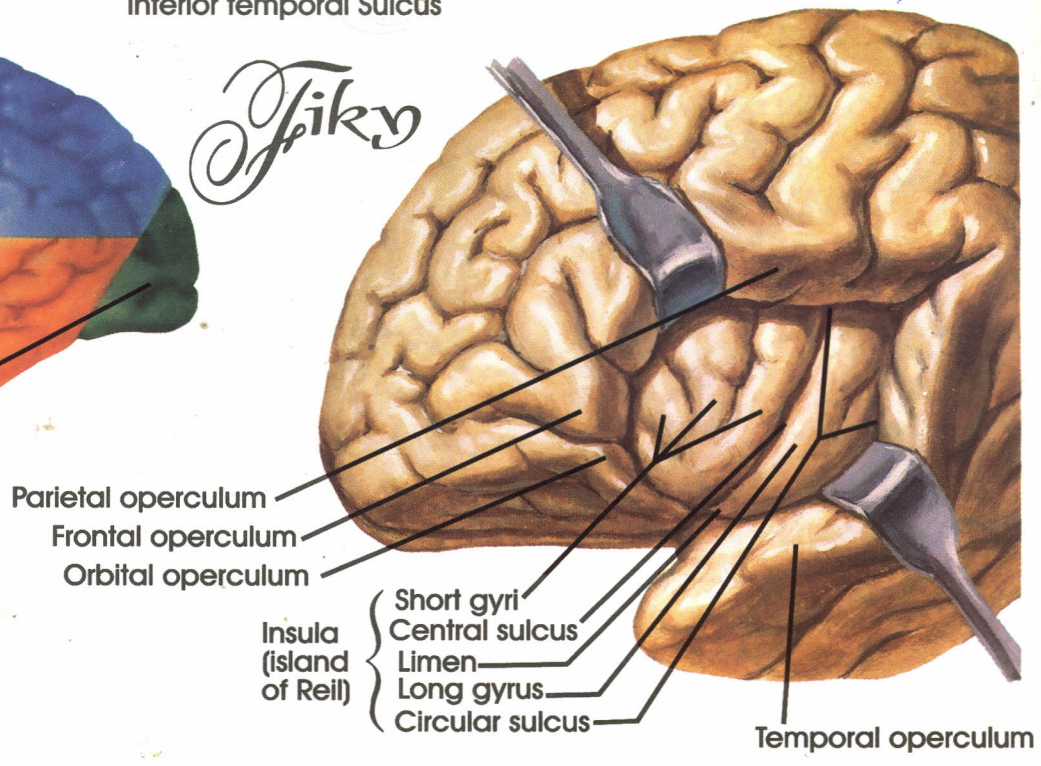
Meninges And Brain



Meninges and Superficial Cerebral Veins

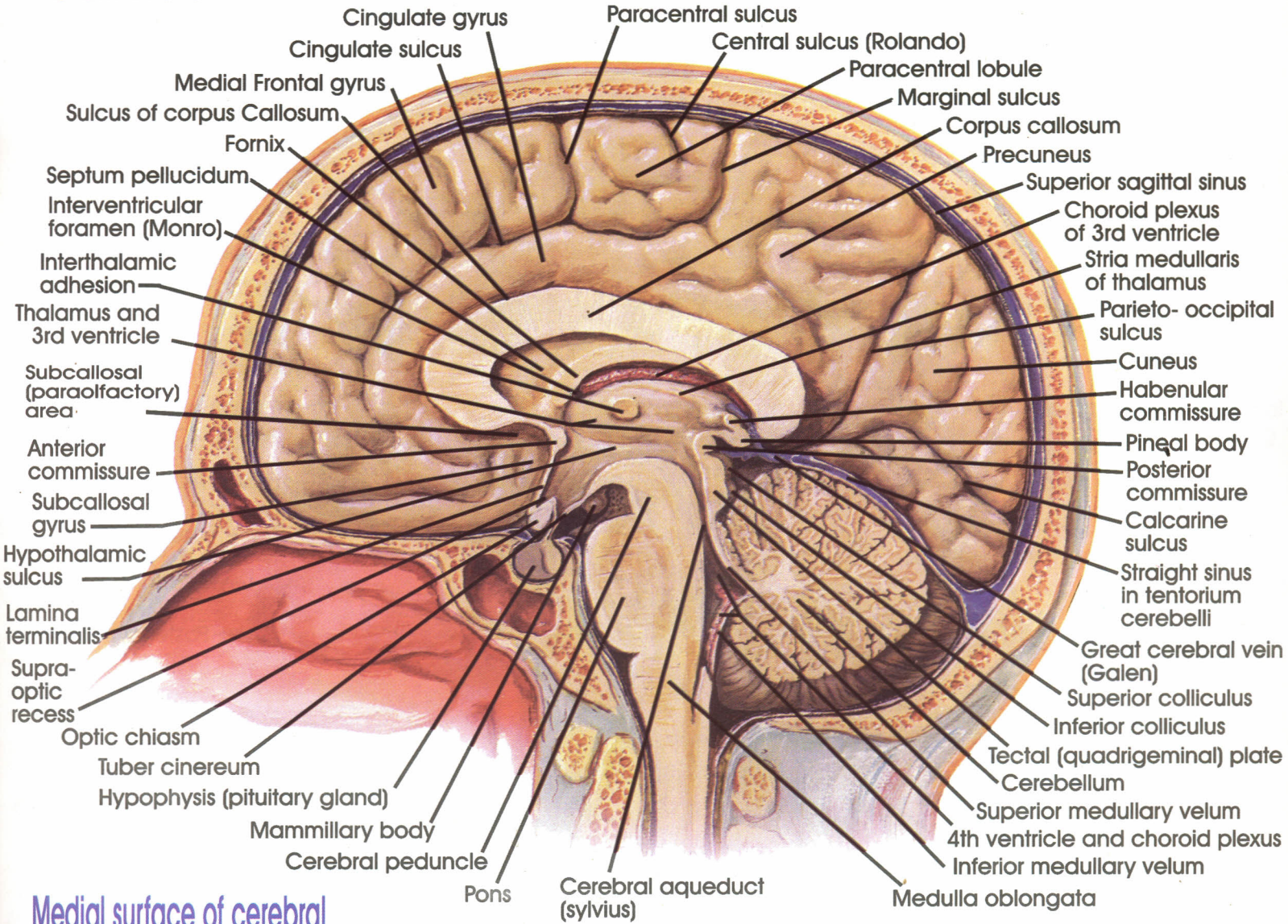


Fiky

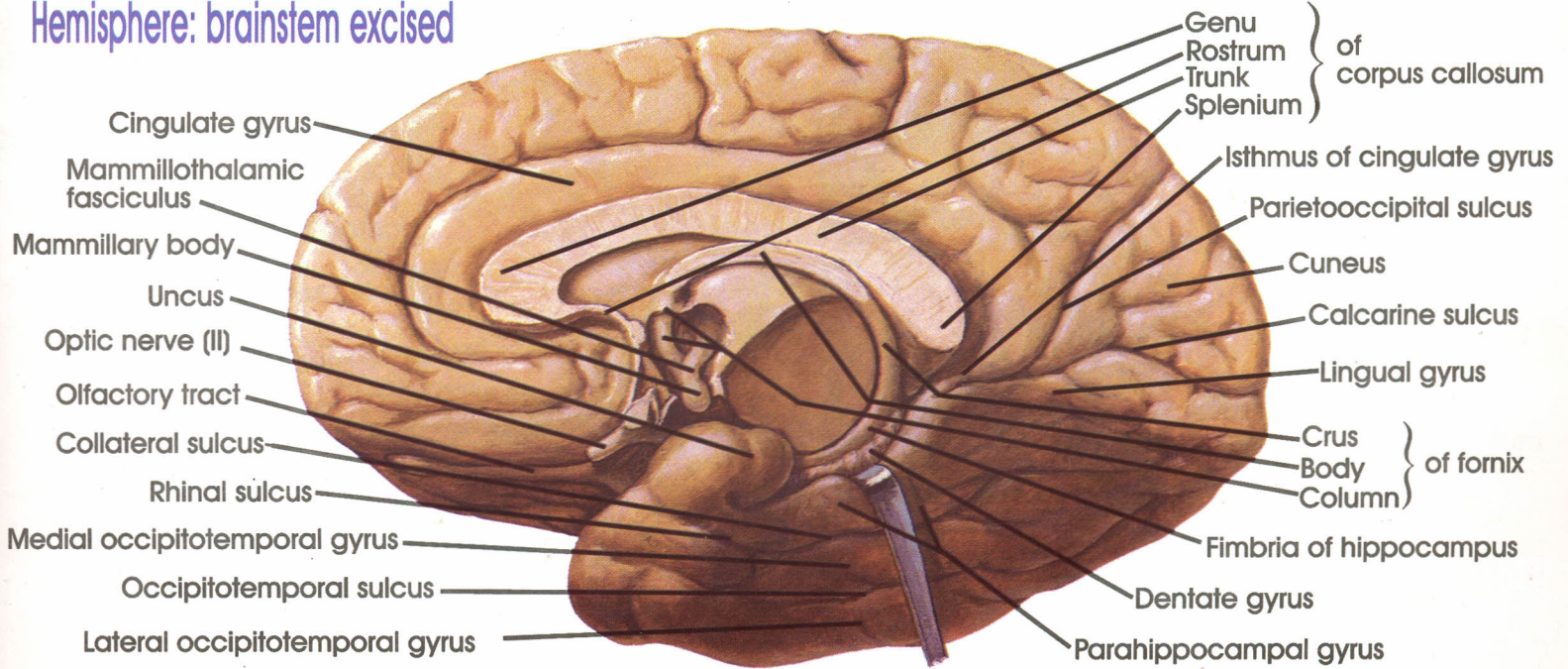


Cerebrum: Lateral Views

Sagittal section of brain in situ

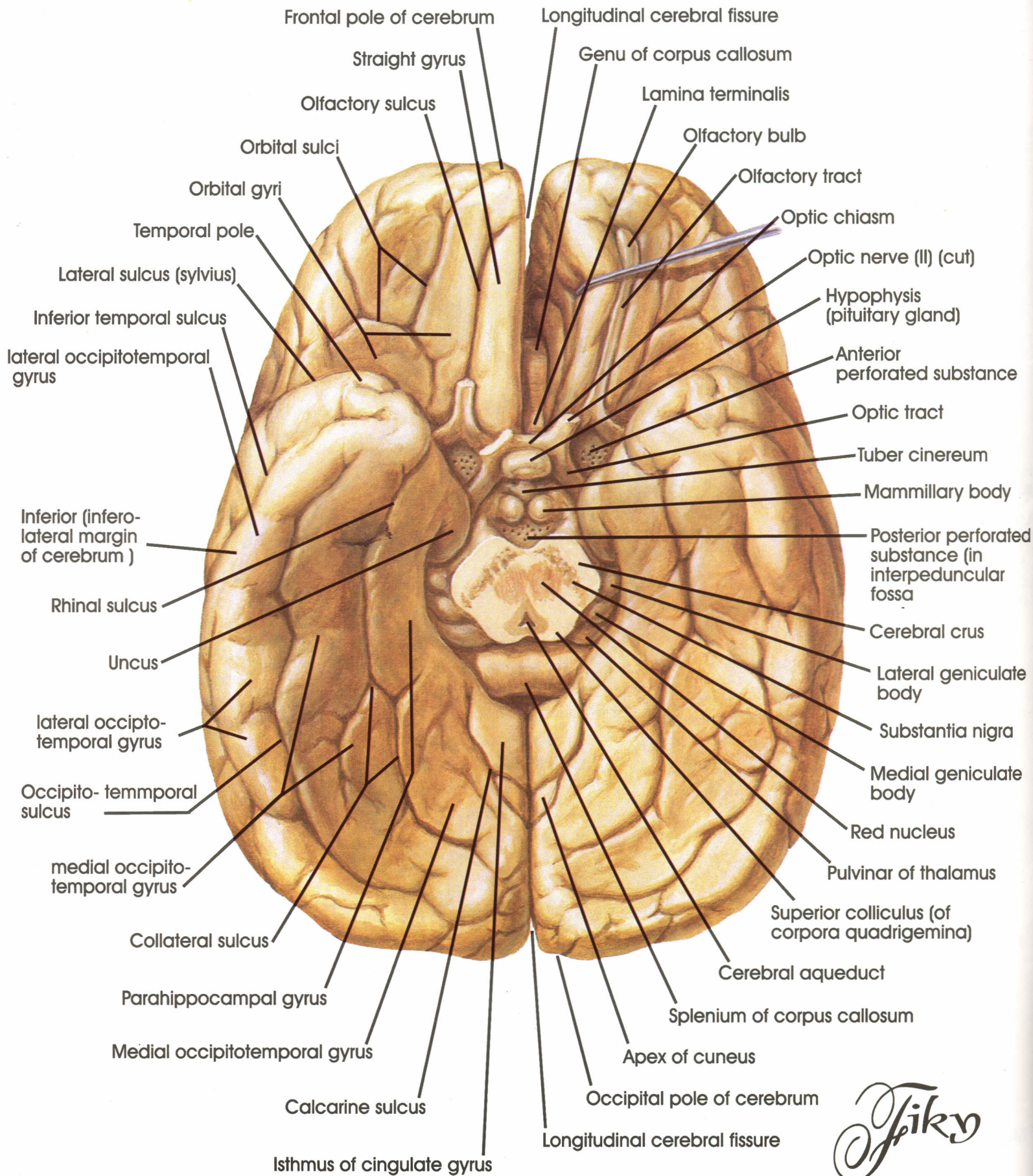


Medial surface of cerebral Hemisphere: brainstem excised



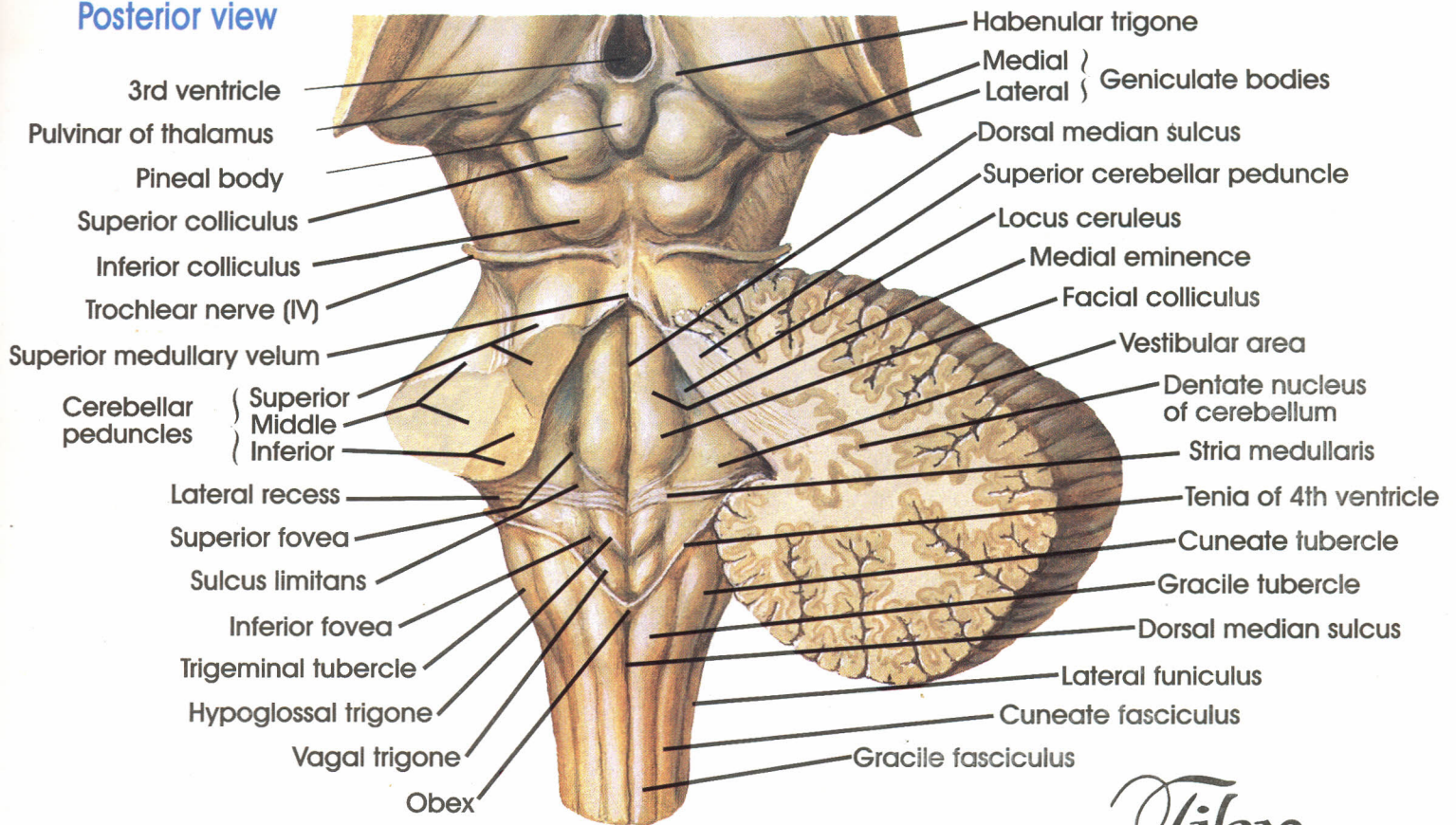
Cerebrum: Medial Views

Fiky



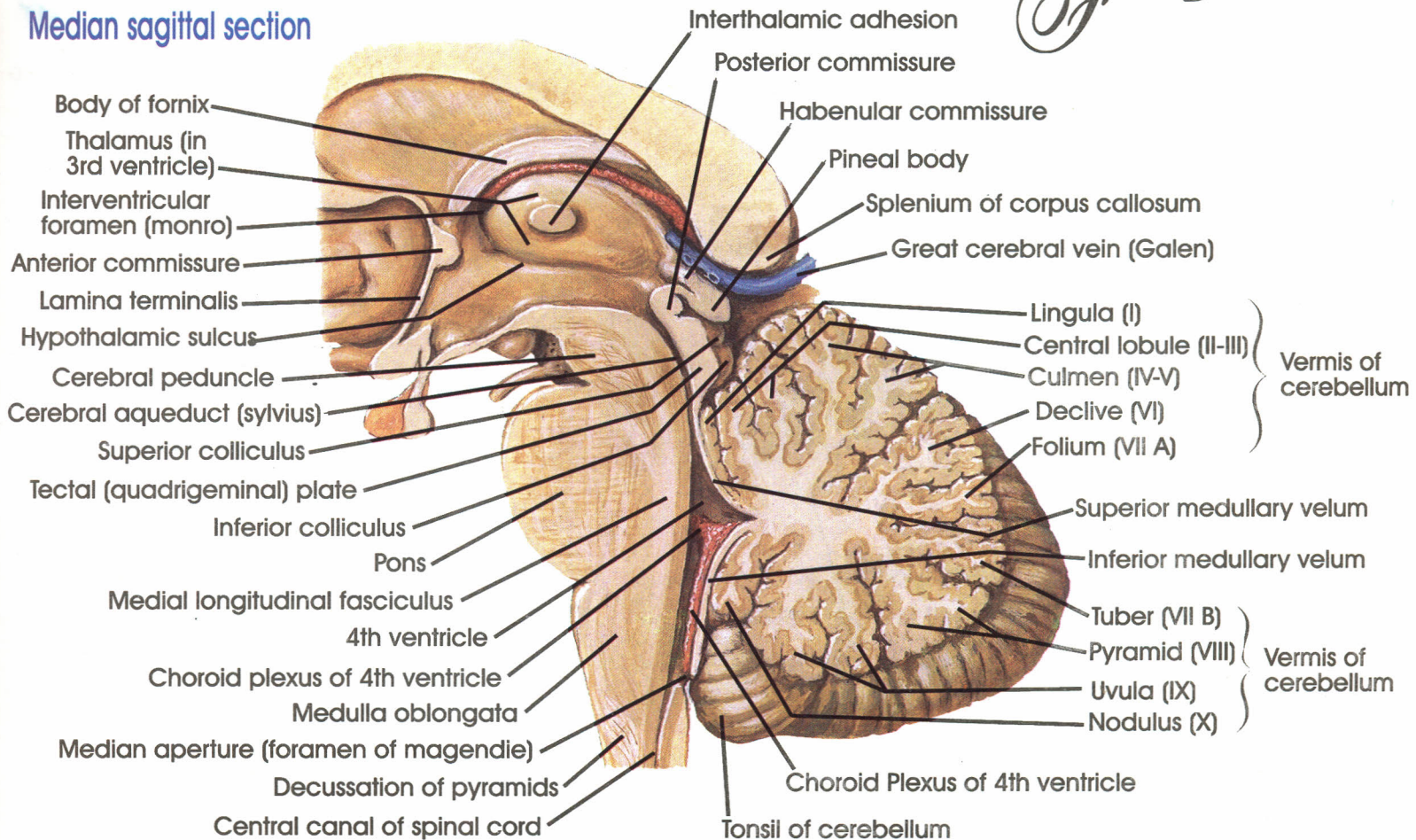
Cerebrum: Inferior View

Posterior view



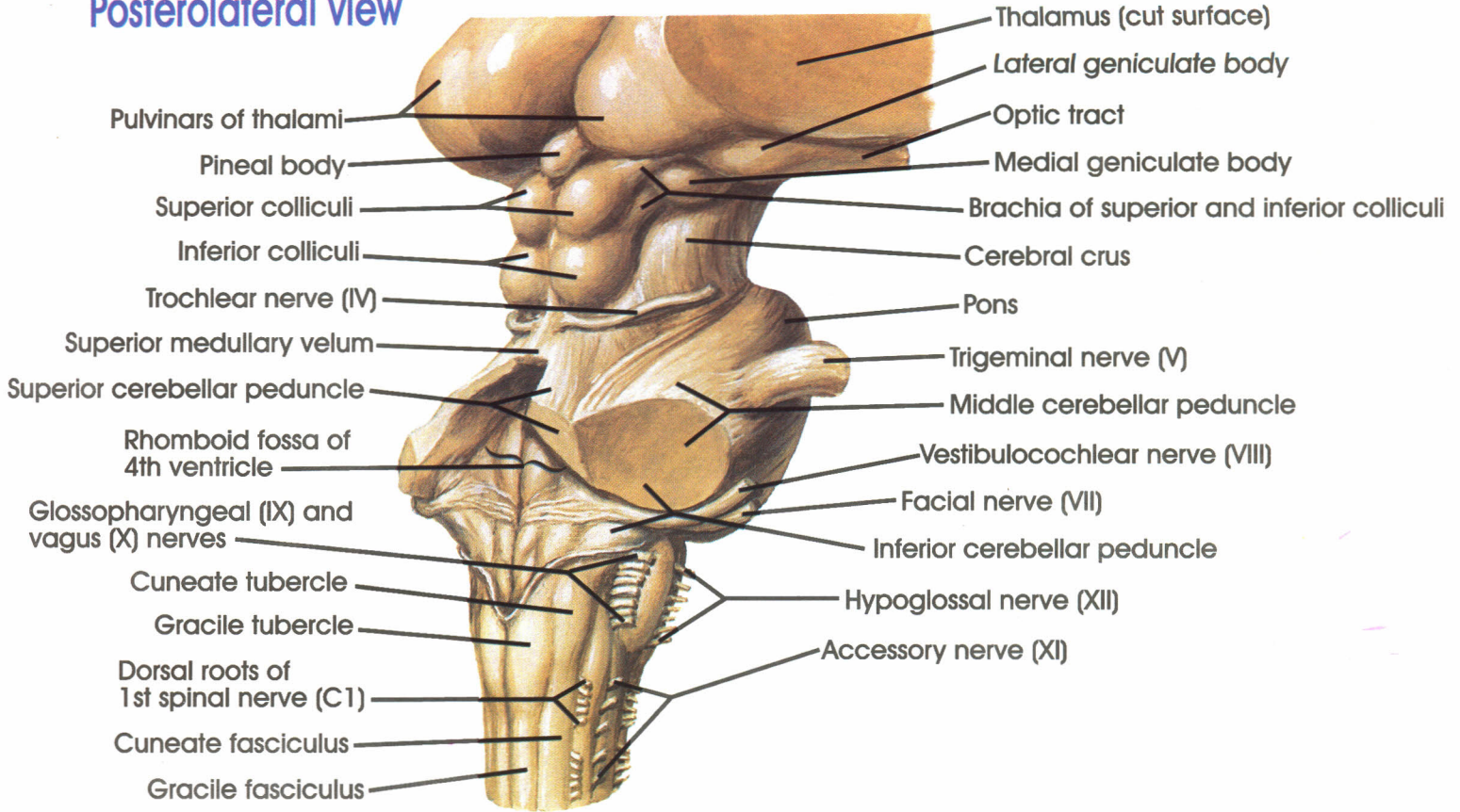
Fiky

Median sagittal section

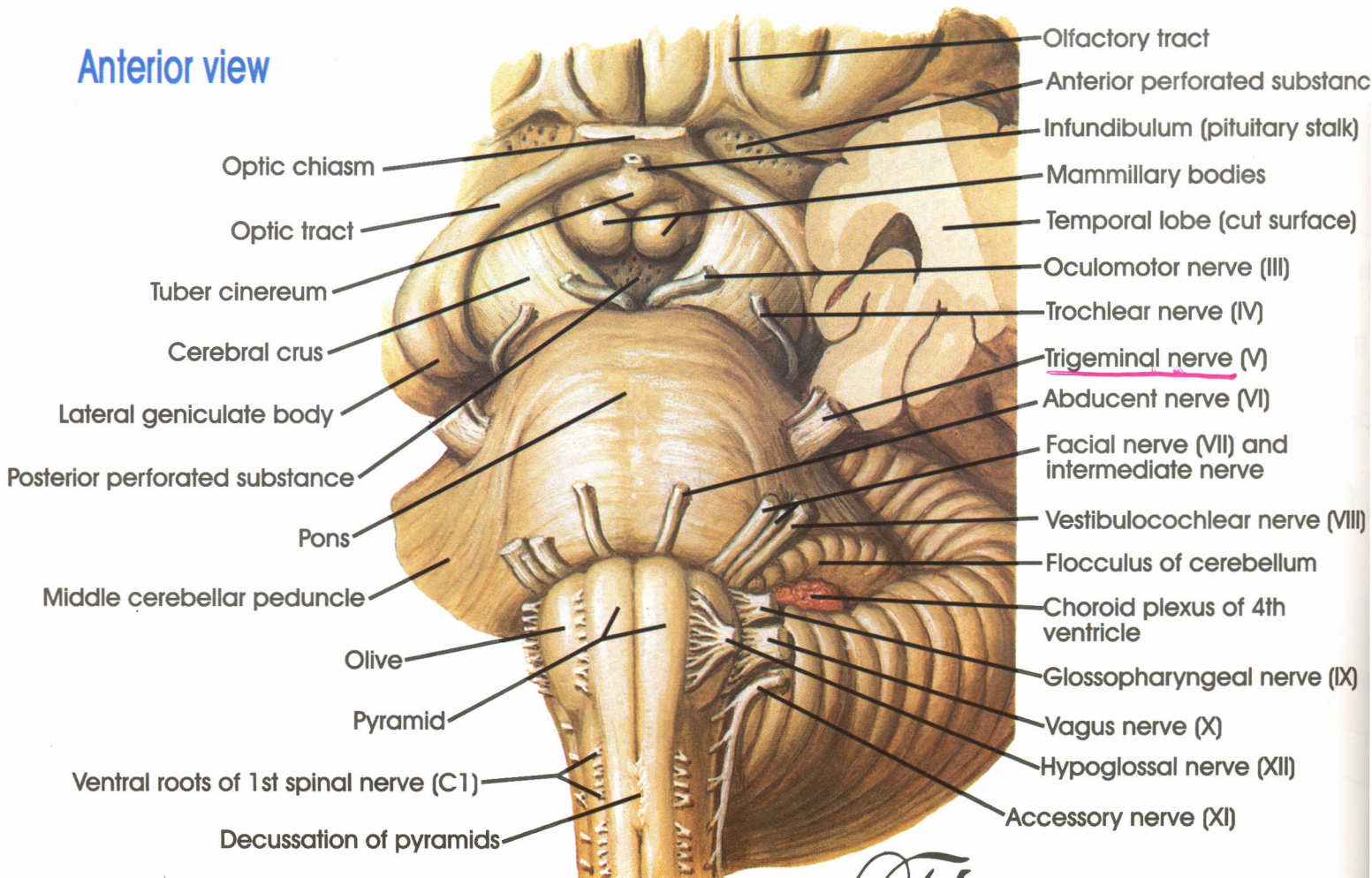


Fourth Ventricle and Cerebellum

Posterolateral view



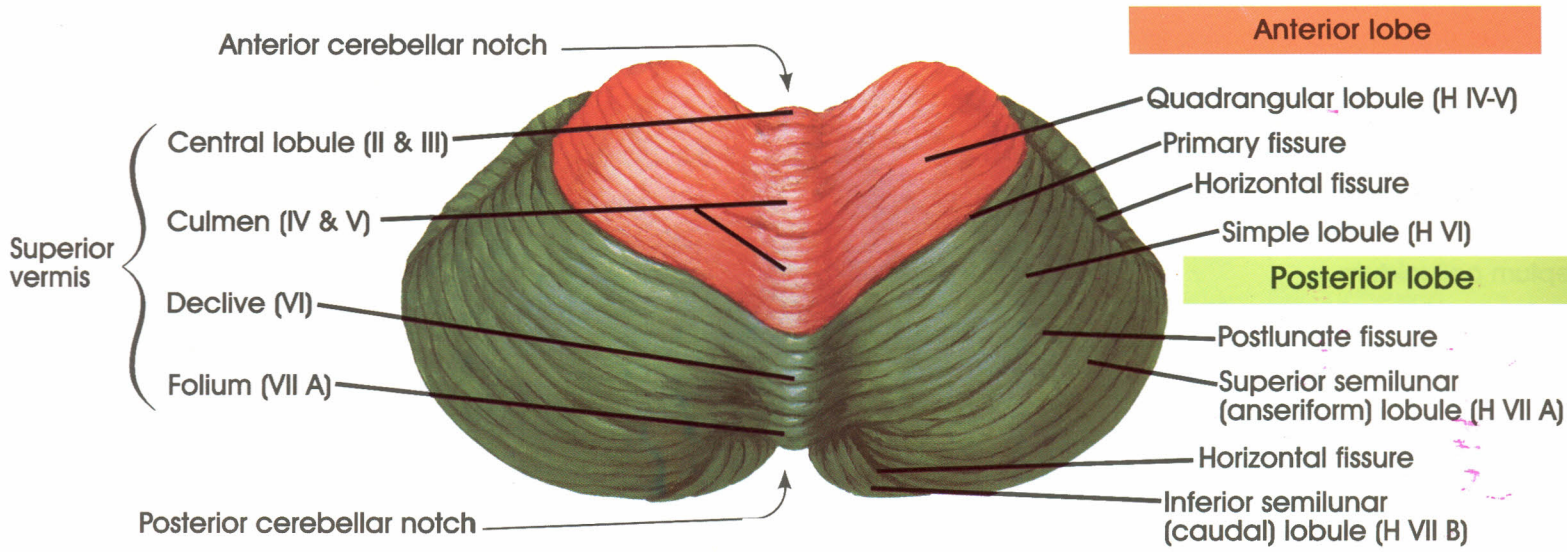
Anterior view



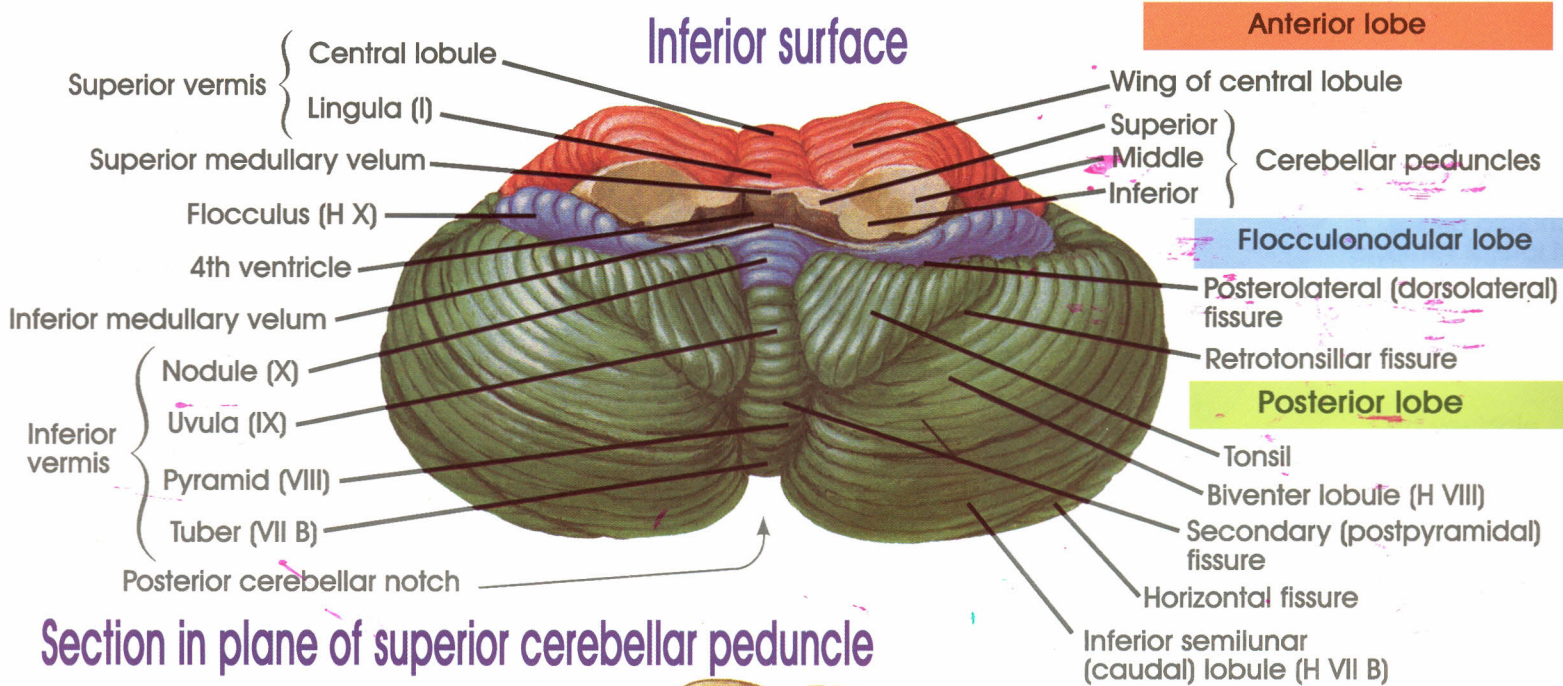
Brainstem

Spiky

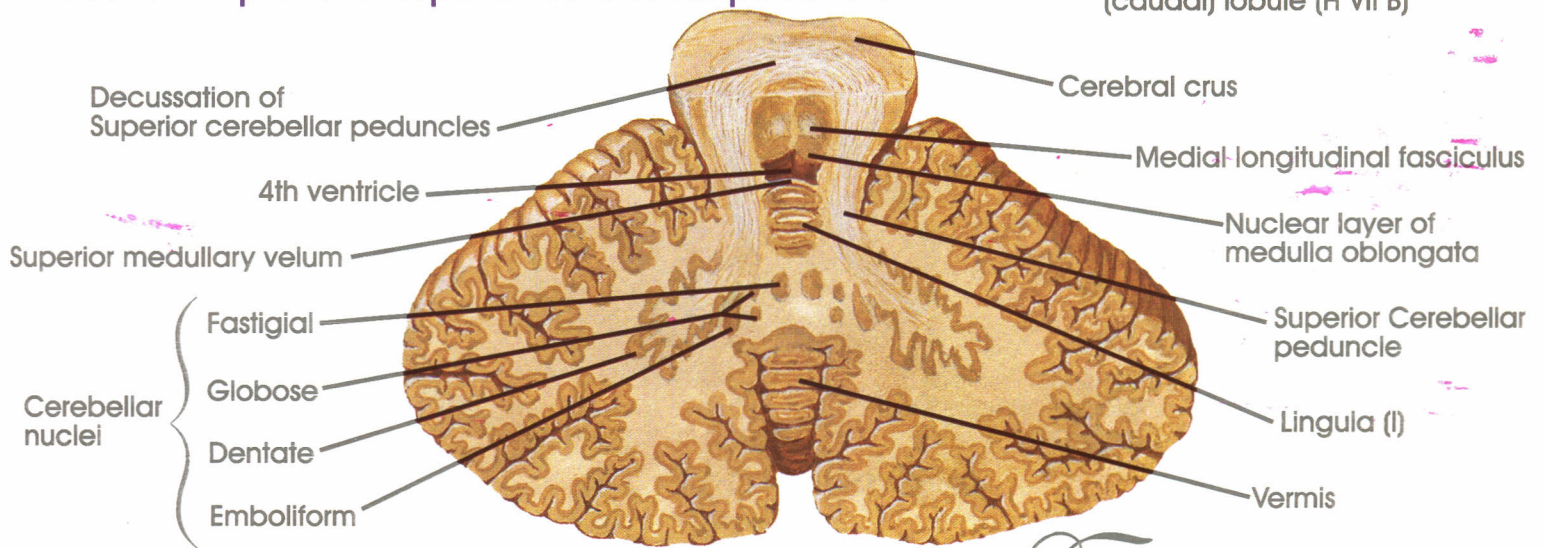
Superior surface



Inferior surface



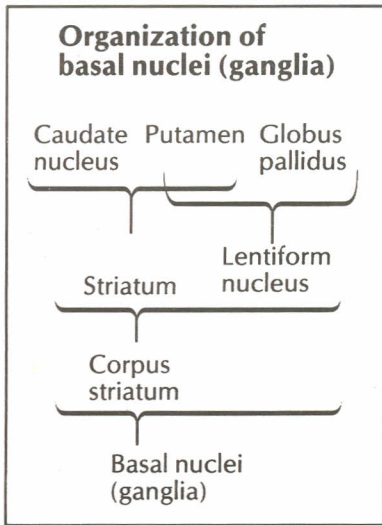
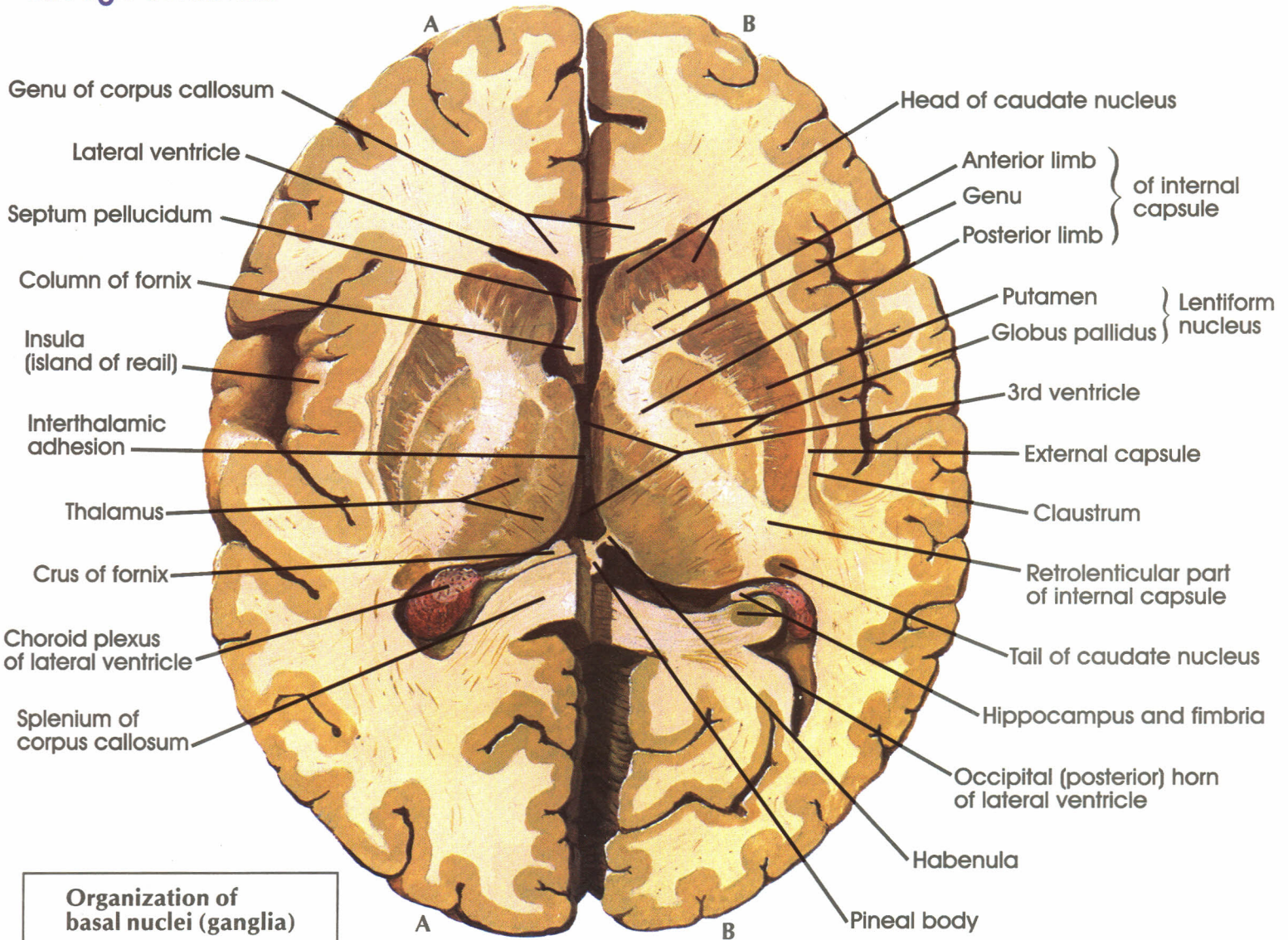
Section in plane of superior cerebellar peduncle



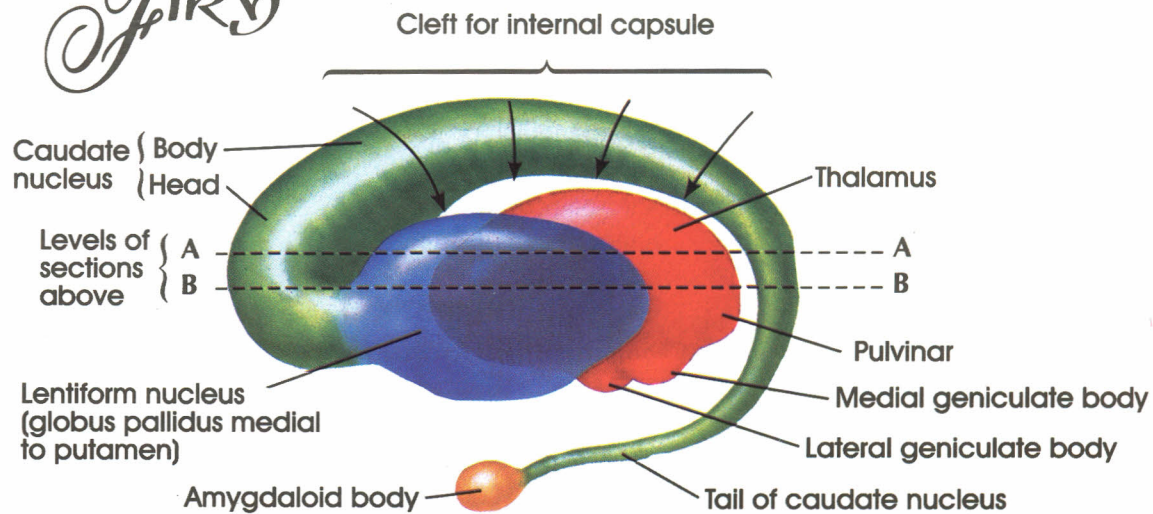
Cerebellum

El-Fiky

Horizontal sections through cerebrum

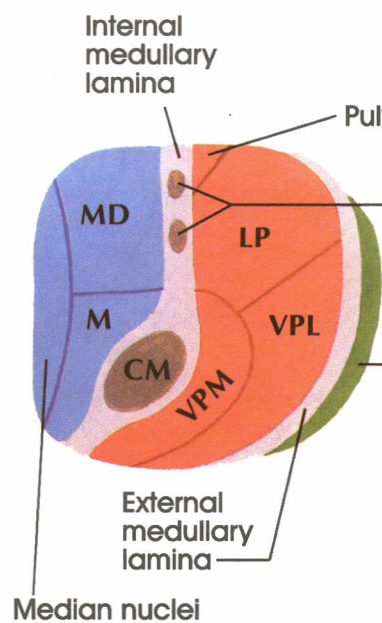
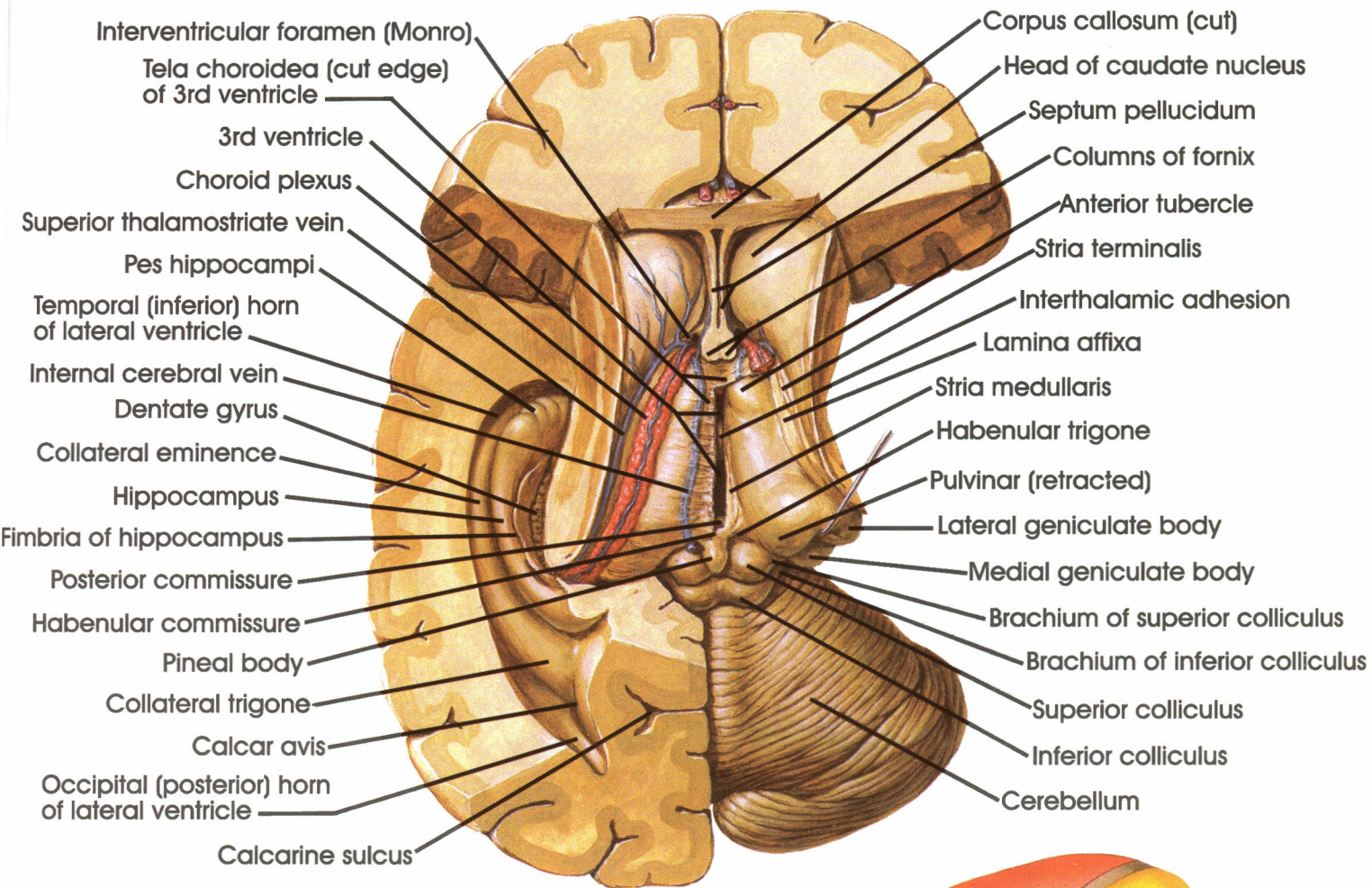


Fiky



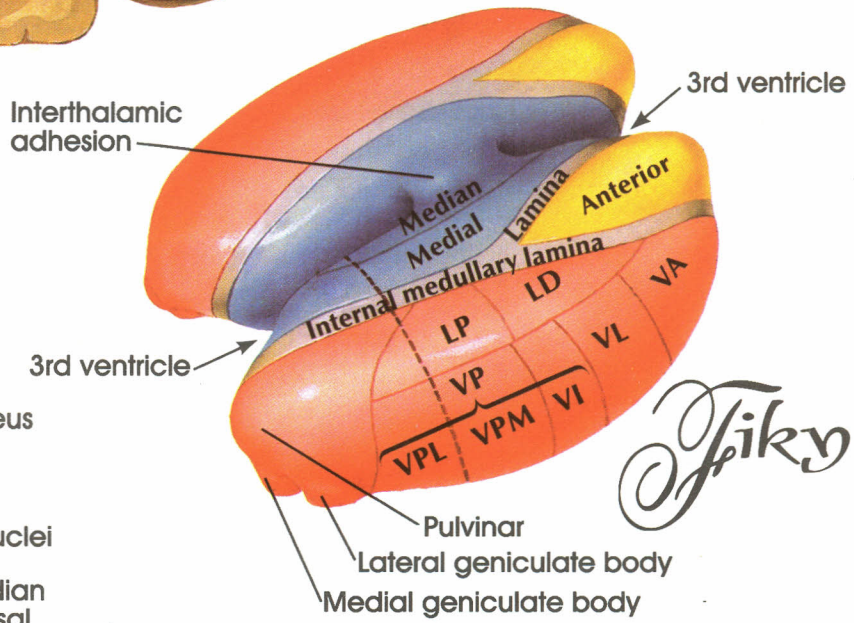
Interrelationship of thalamus, lentiform nucleus, caudate nucleus and amygdaloid body (schema): left lateral view

Basal Nuclei (Ganglia)



Schematic section through thalamus (at level of broken line shown in figure at right)

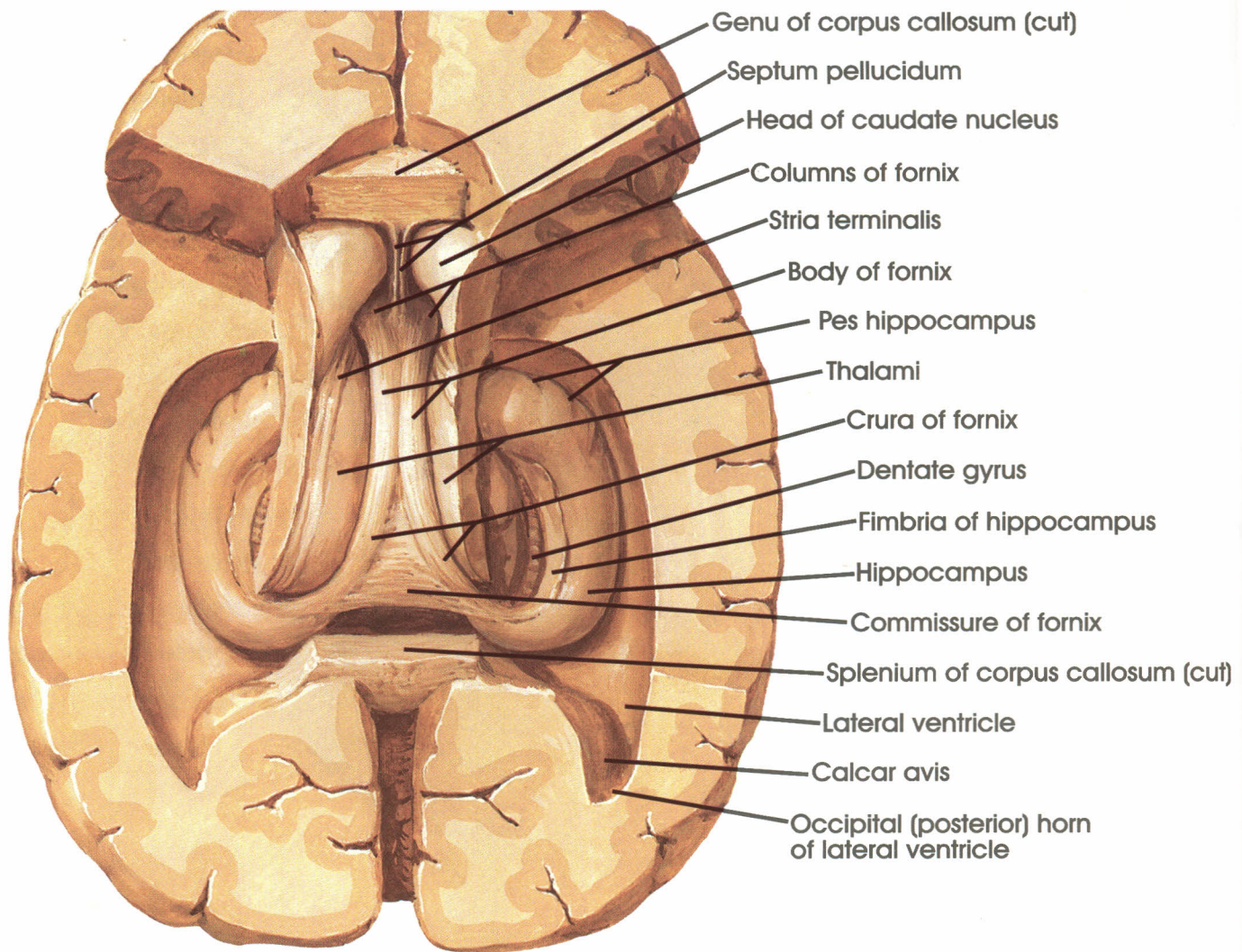
- Thalamic nuclei
- CM Centromedian
 - LD Lateral dorsal
 - LP Lateral Posterior
 - M Medial
 - MD Medial dorsal
 - VA Ventral anterior
 - VI Ventral intermedial
 - VL Ventral lateral
 - VP Ventral posterior
 - VPL Ventral posterolateral
 - VPM ventral posteromedial



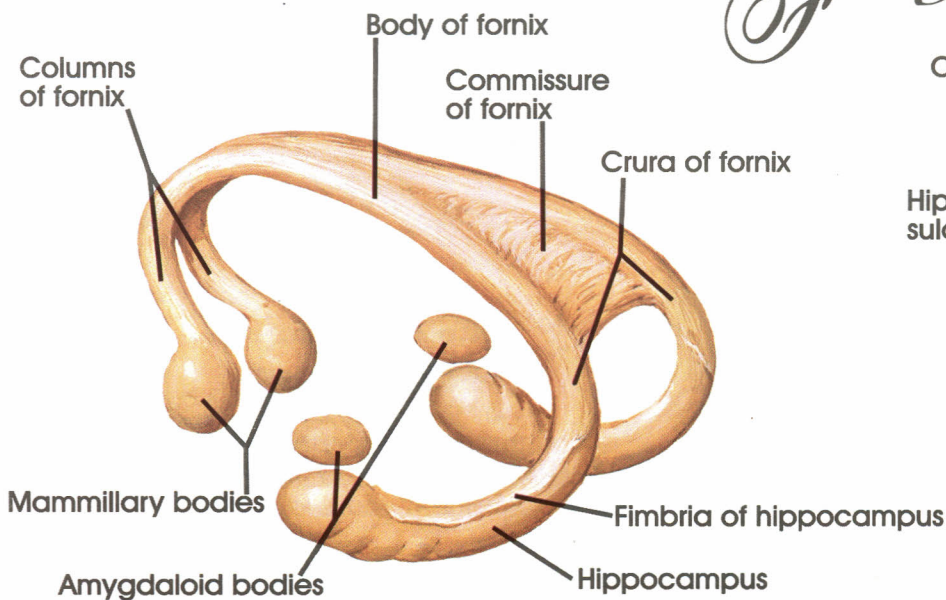
Schematic representation of thalamus (external medullary lamina and reticular nuclei removed)

- Lateral nuclei
- Medial nuclei
- Anterior nuclei

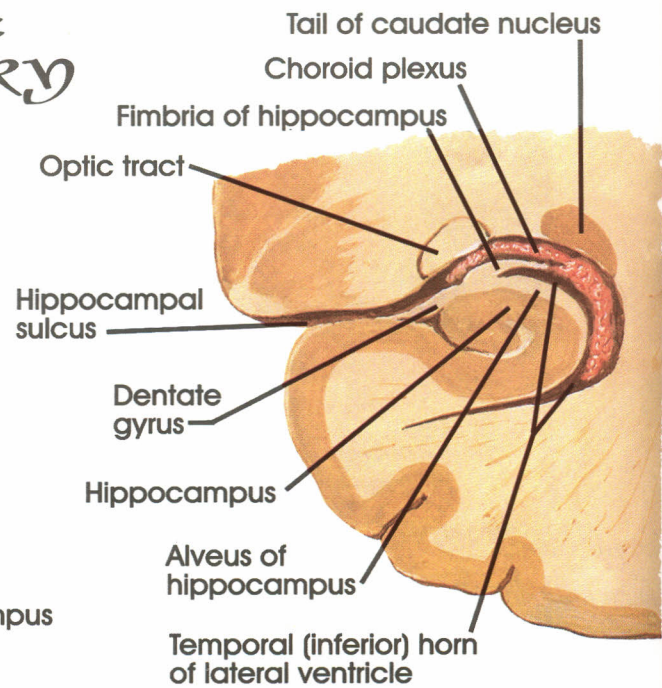
Thalamus



Fiky

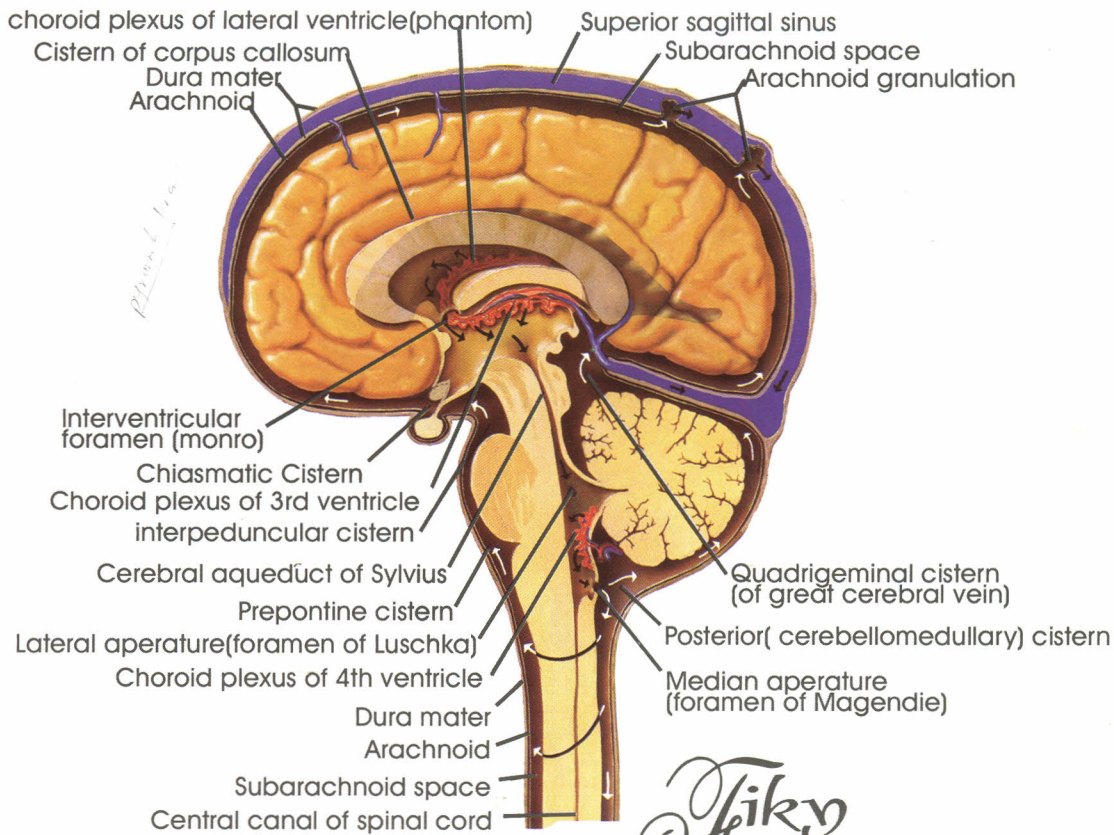


Fornix: schema



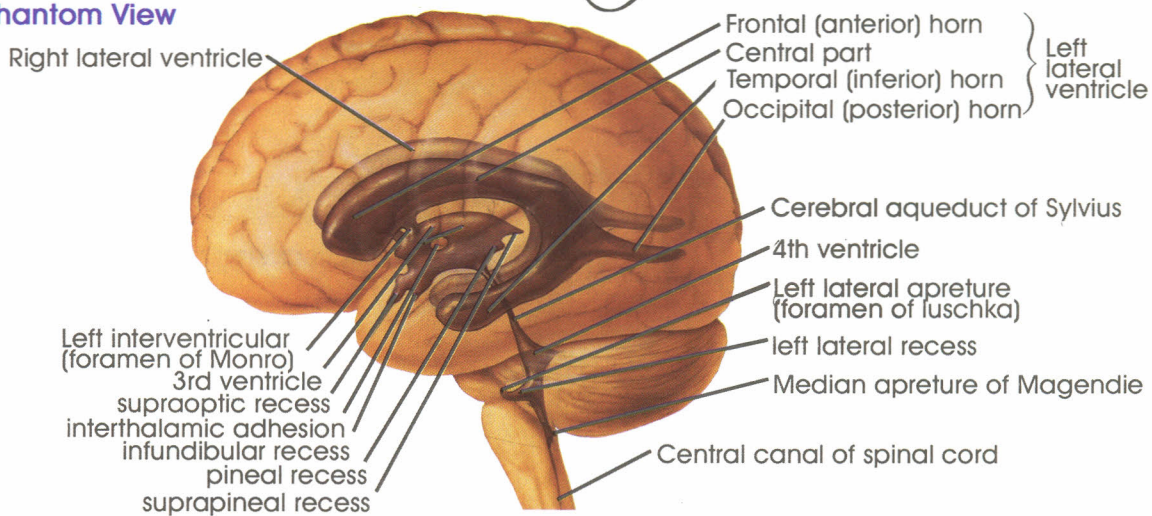
Coronal section: Posterior View

Hippocampus and Fornix

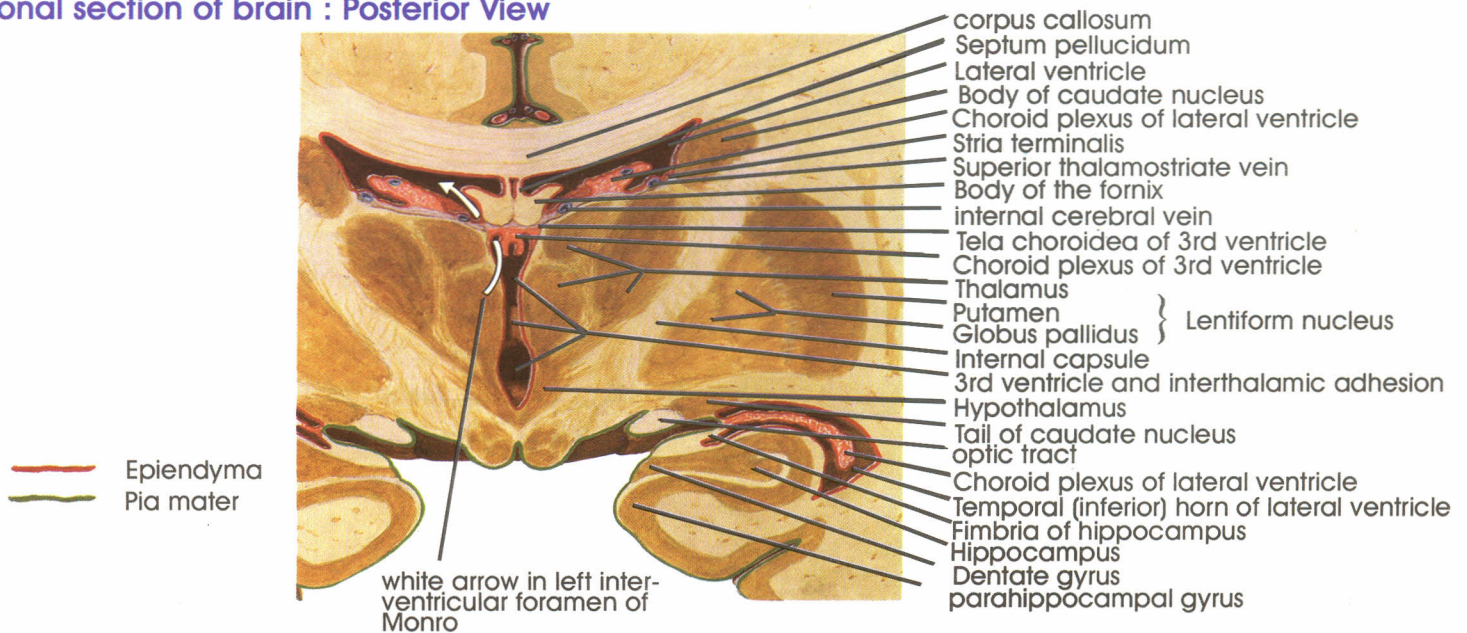


Fiky

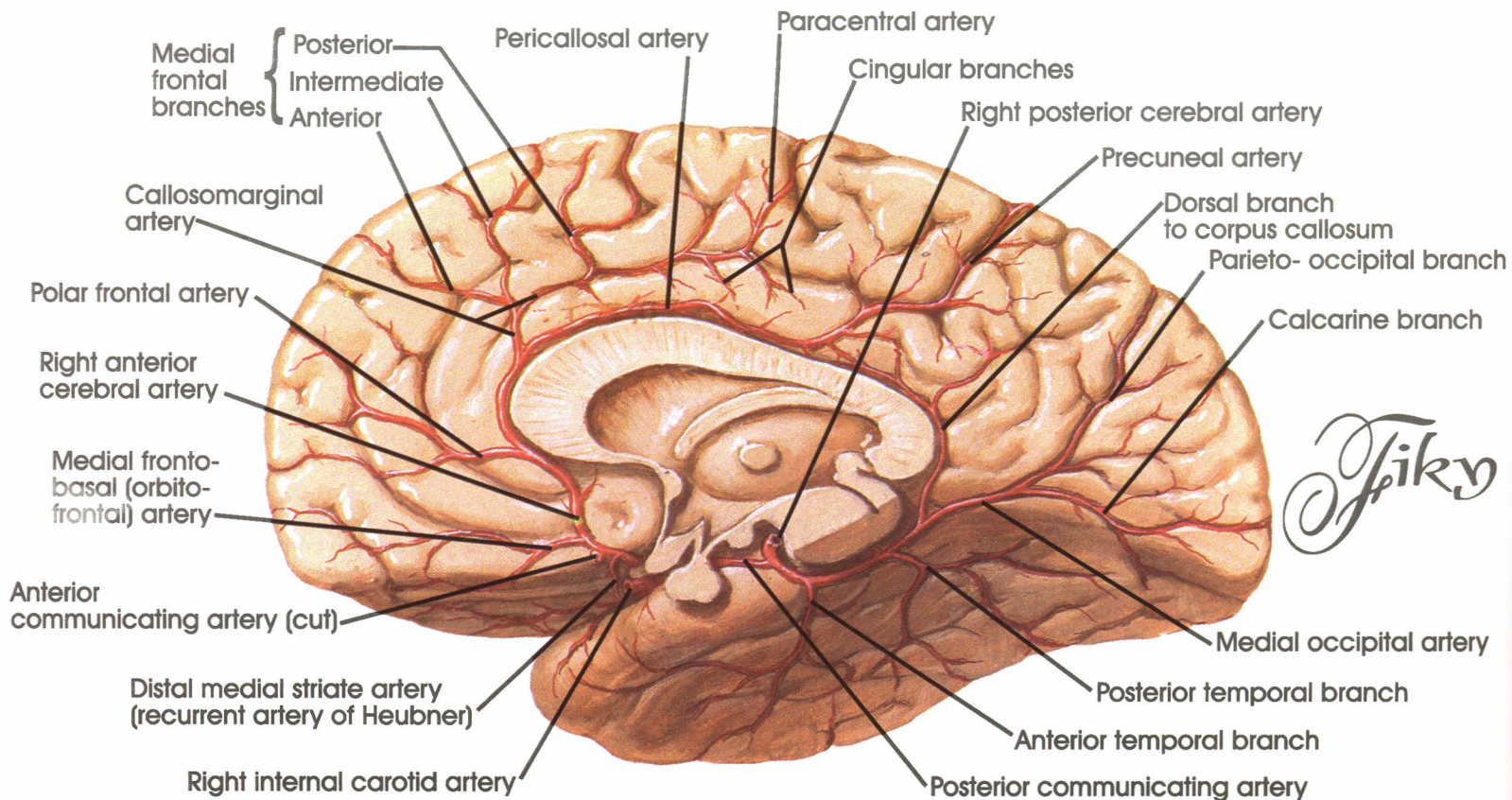
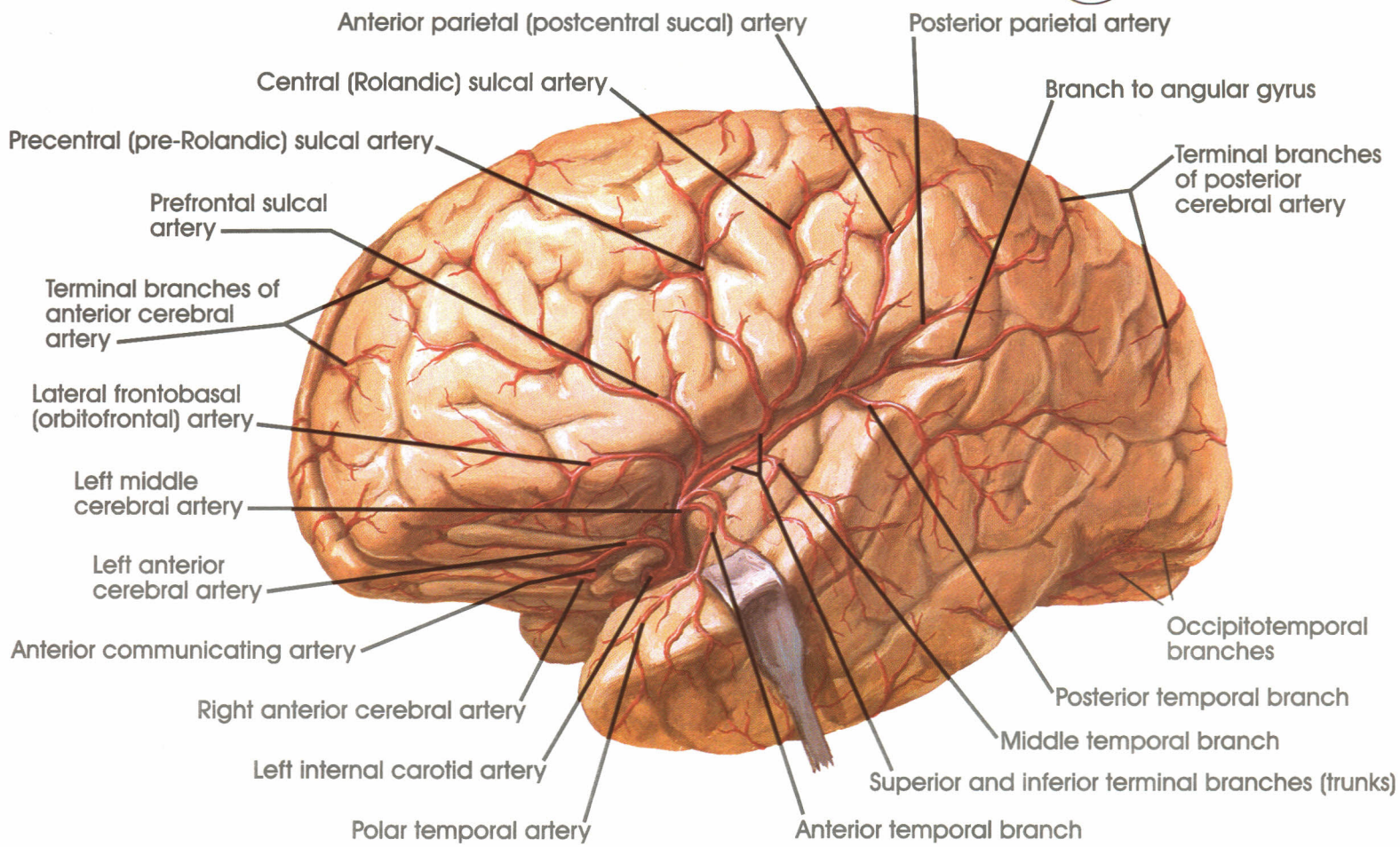
Left Lateral Phantom View



Coronal section of brain : Posterior View

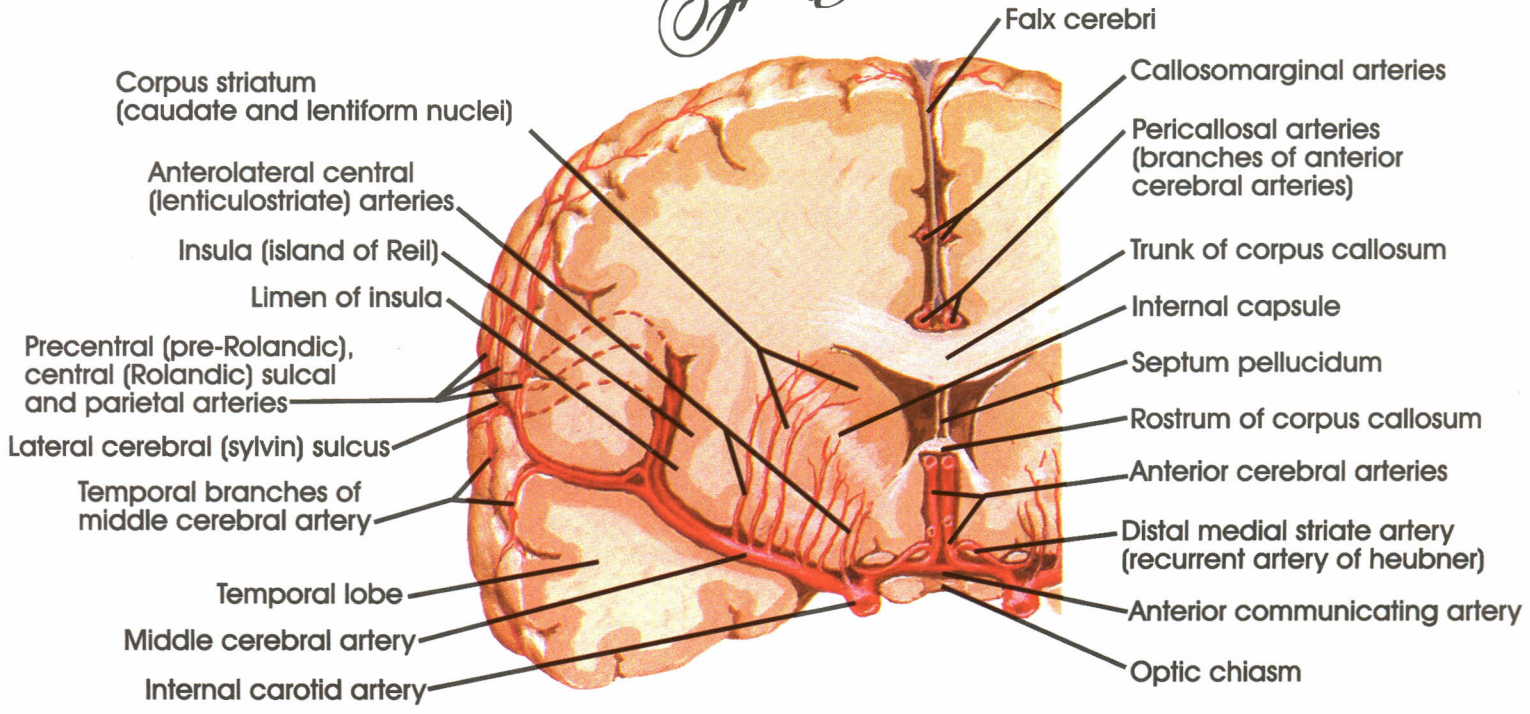
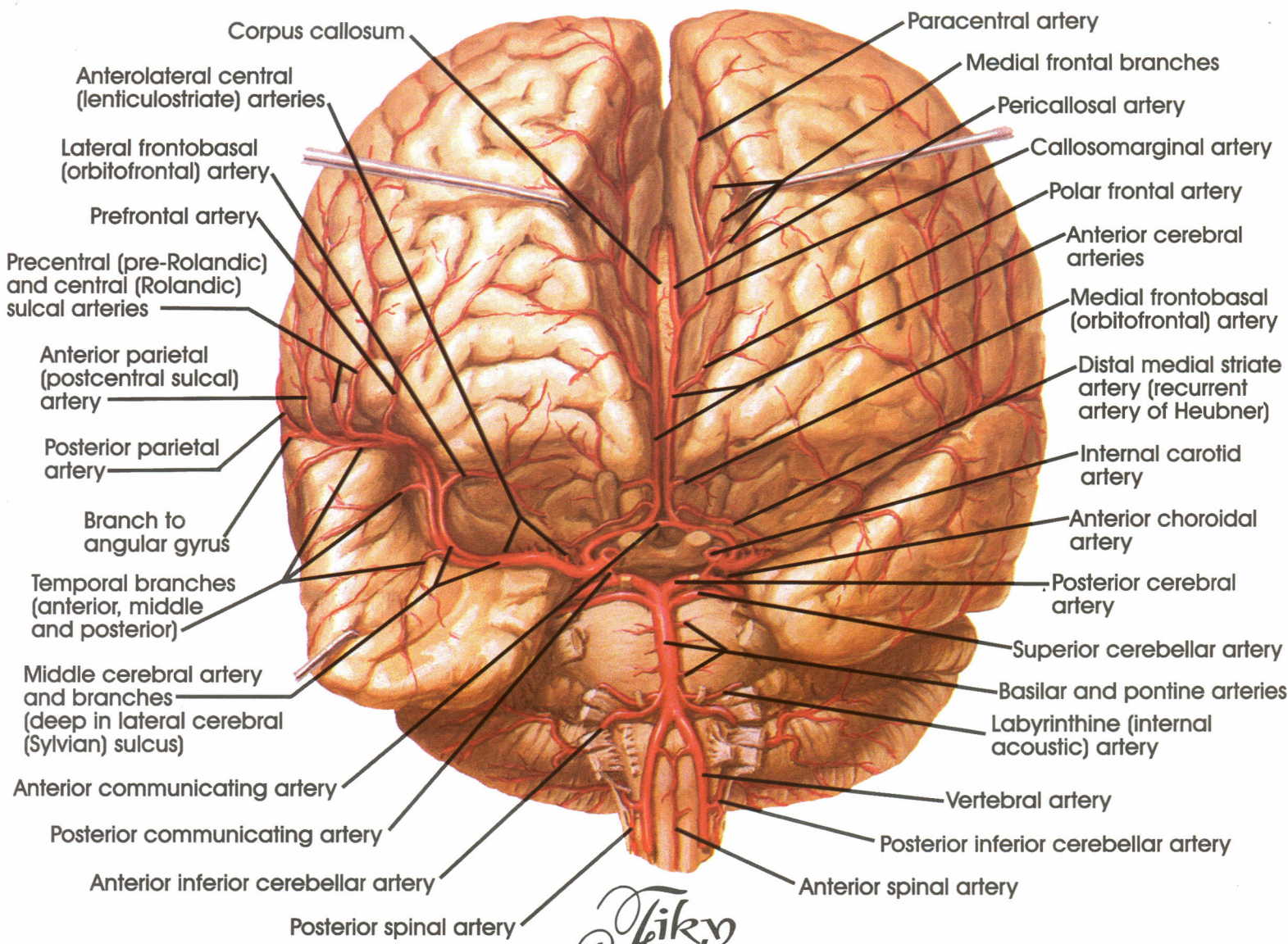


Ventricles of the brain and cerebrospinal fluid circulation

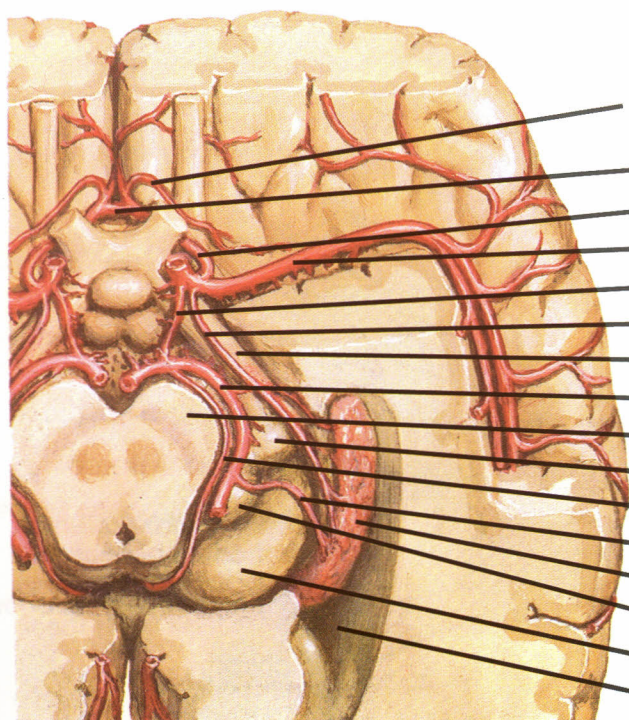
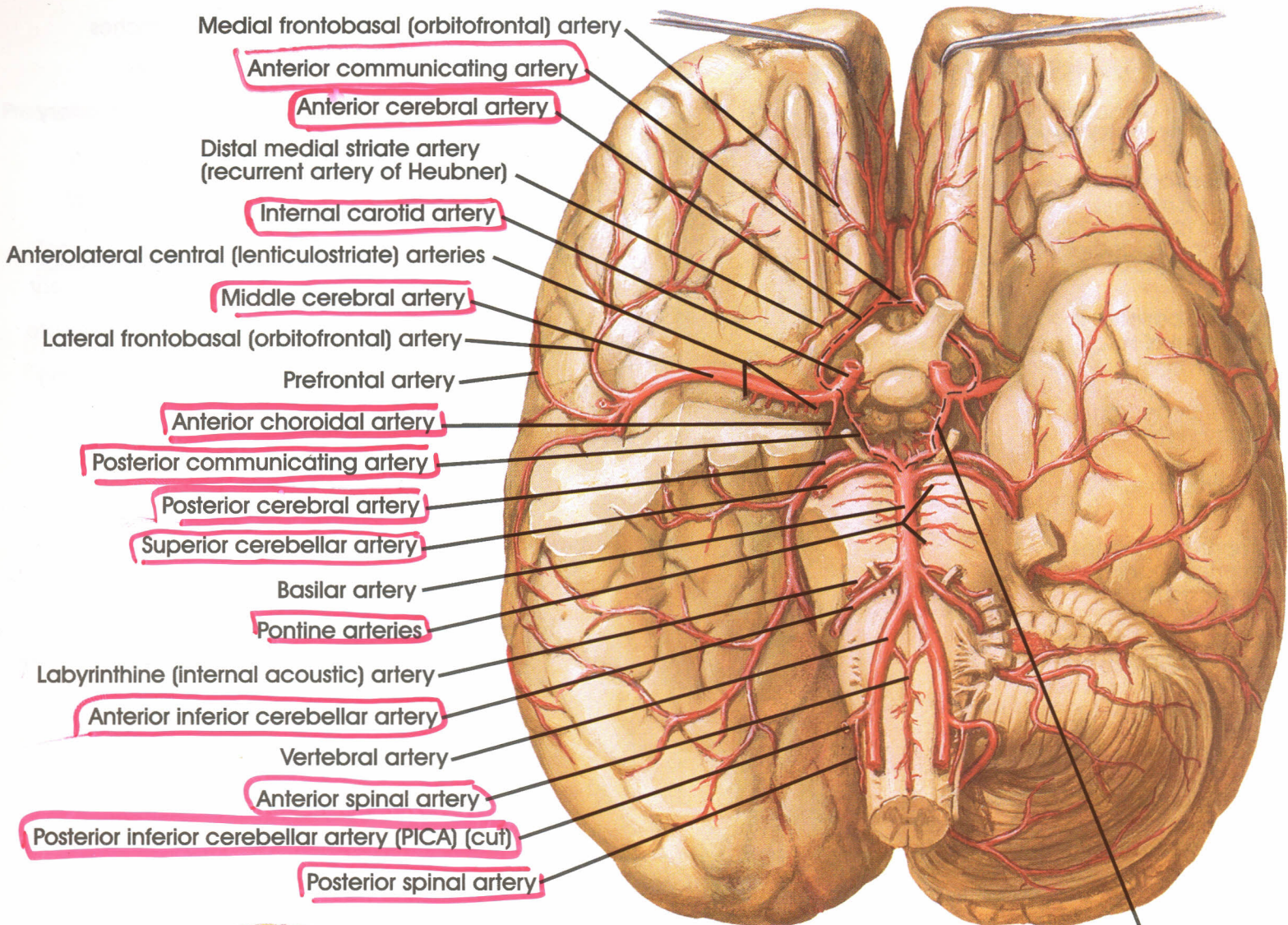


El-Fiky

Arteries of Brain: Lateral and Medial views



Arteries of Brain: Frontal View and Section

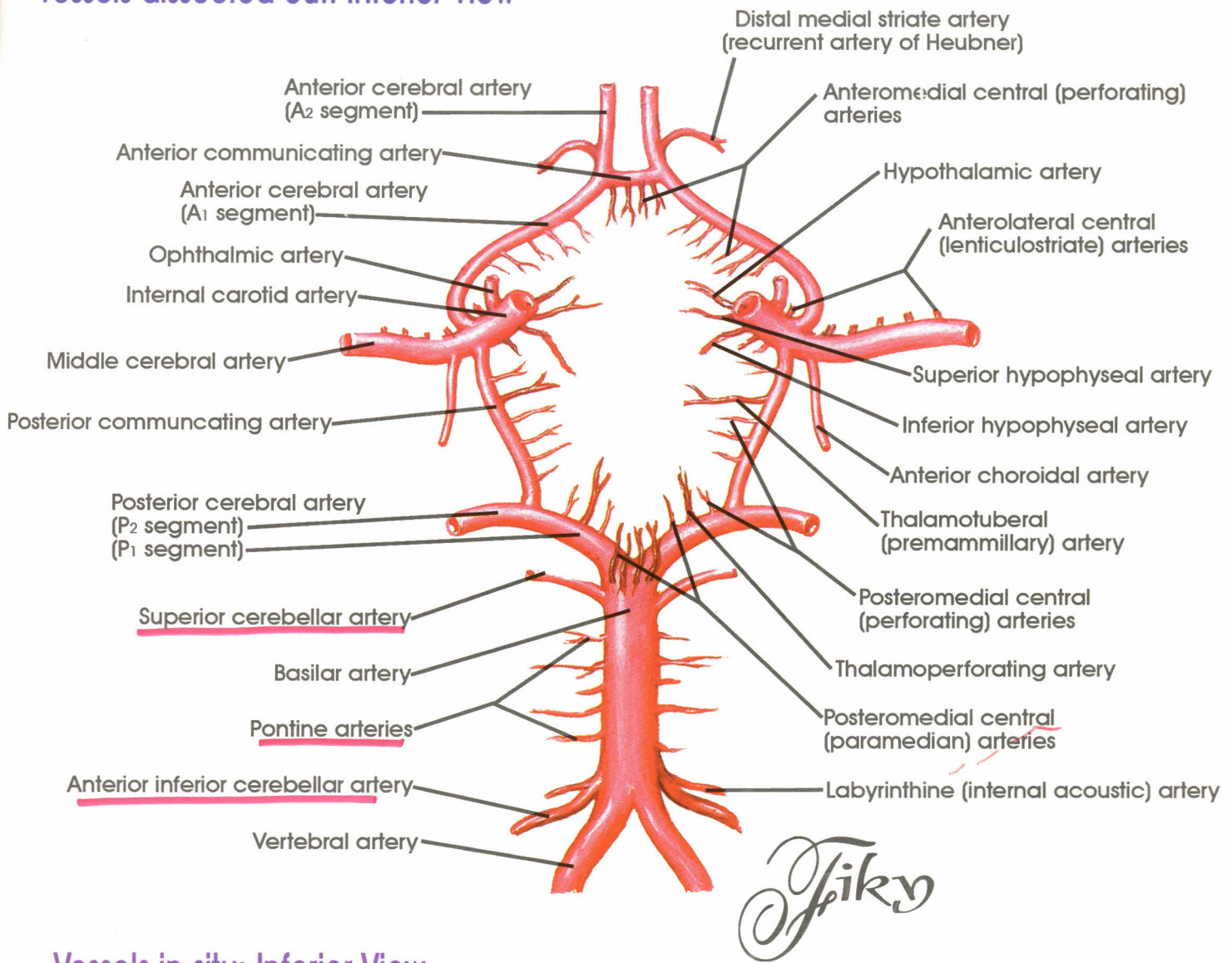


El-Fiky

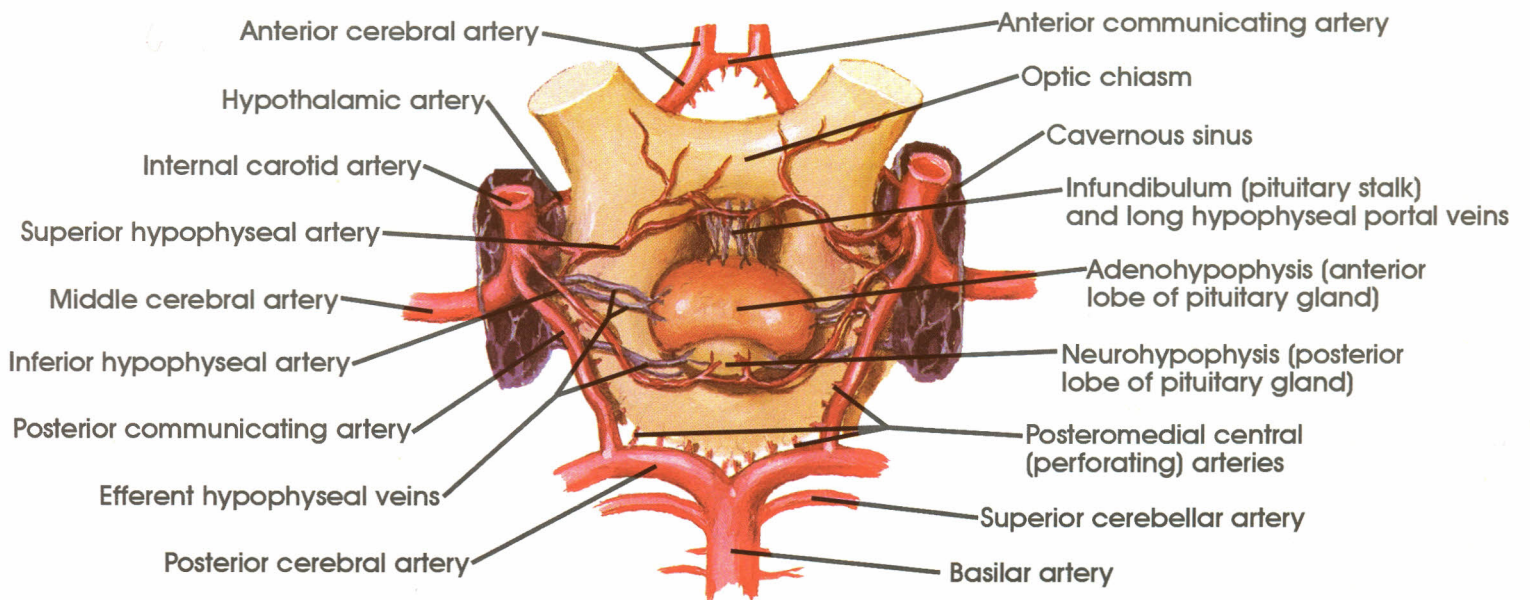
Cerebral arterial circle (Willis) (broken line)

Arteries of Brain: Inferior View

Vessels dissected out: Inferior View

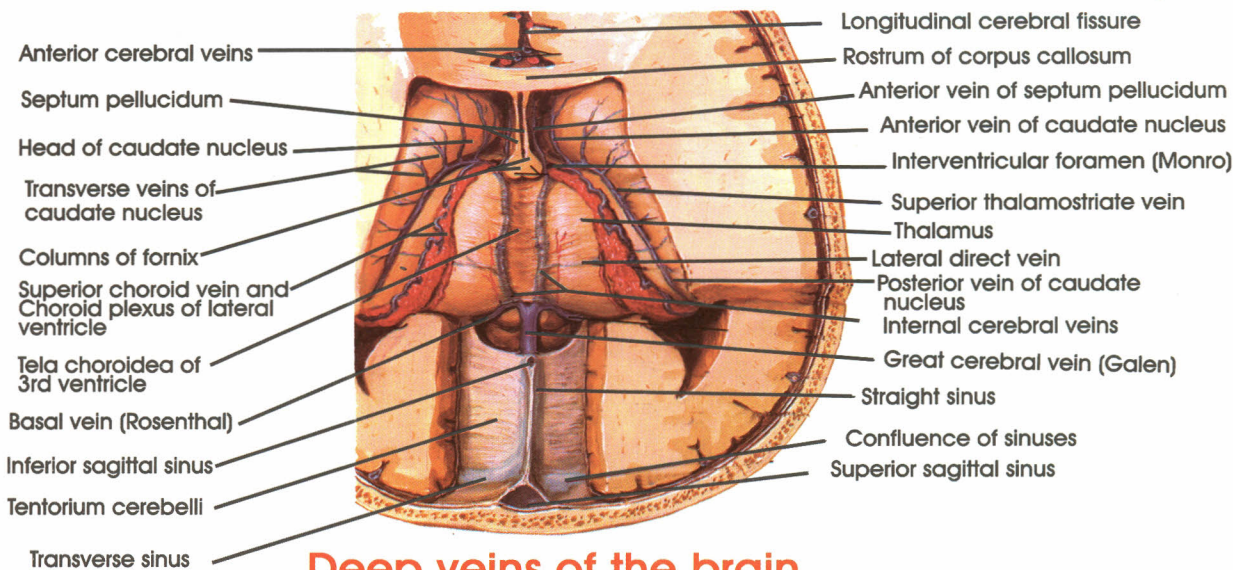


Vessels in situ: Inferior View



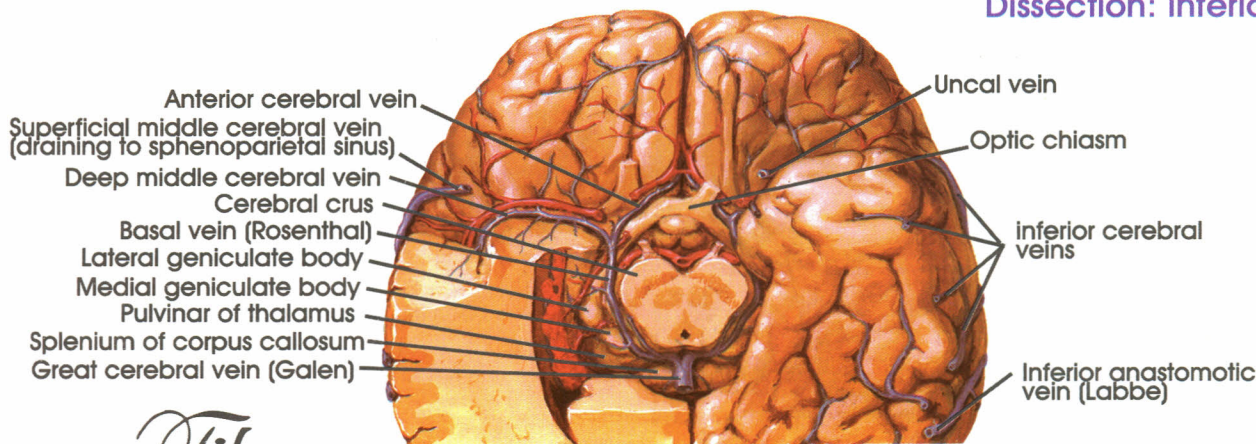
Cerebral Arterial Circle (Willis)

Dissection : superior view



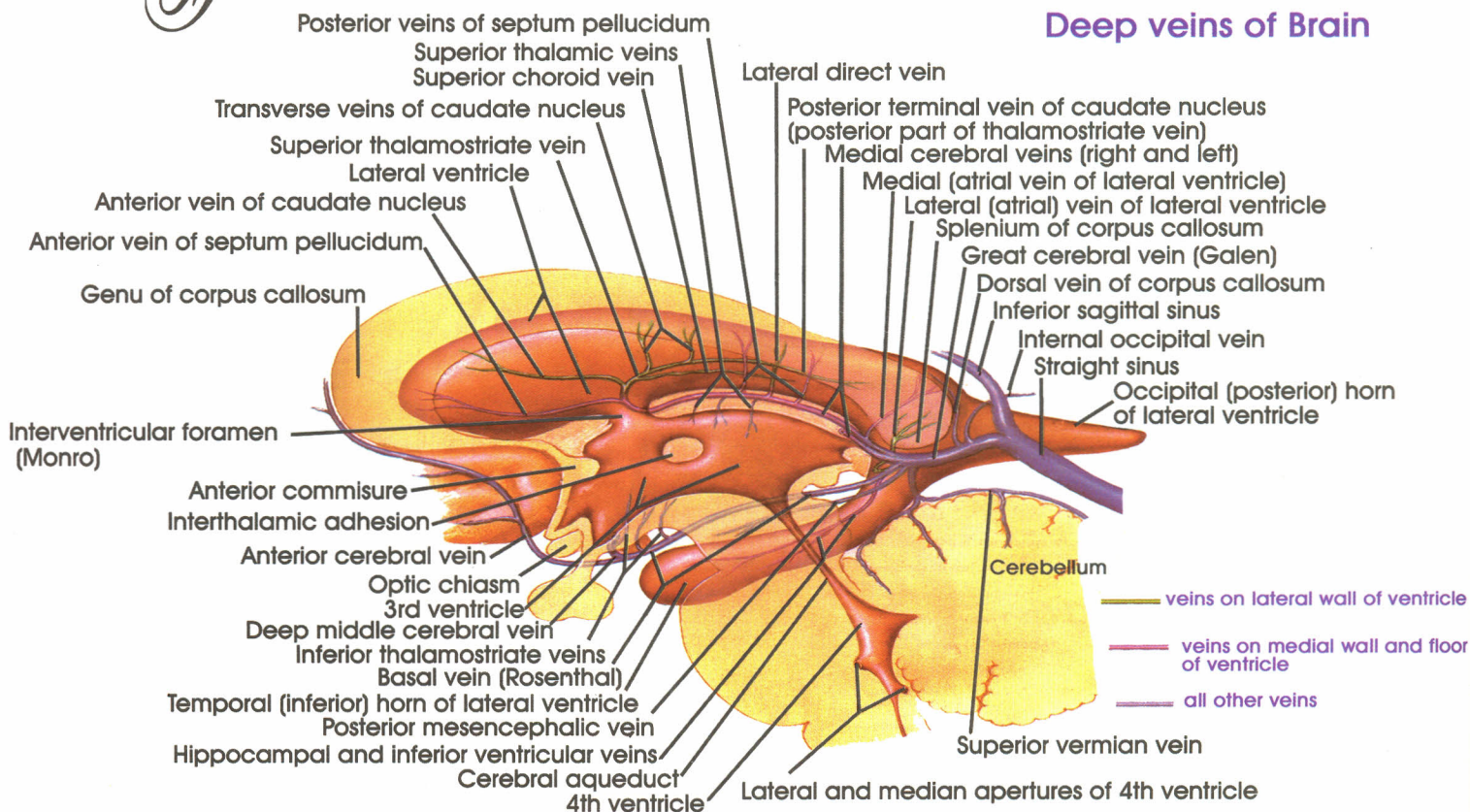
Deep veins of the brain

Dissection: inferior view

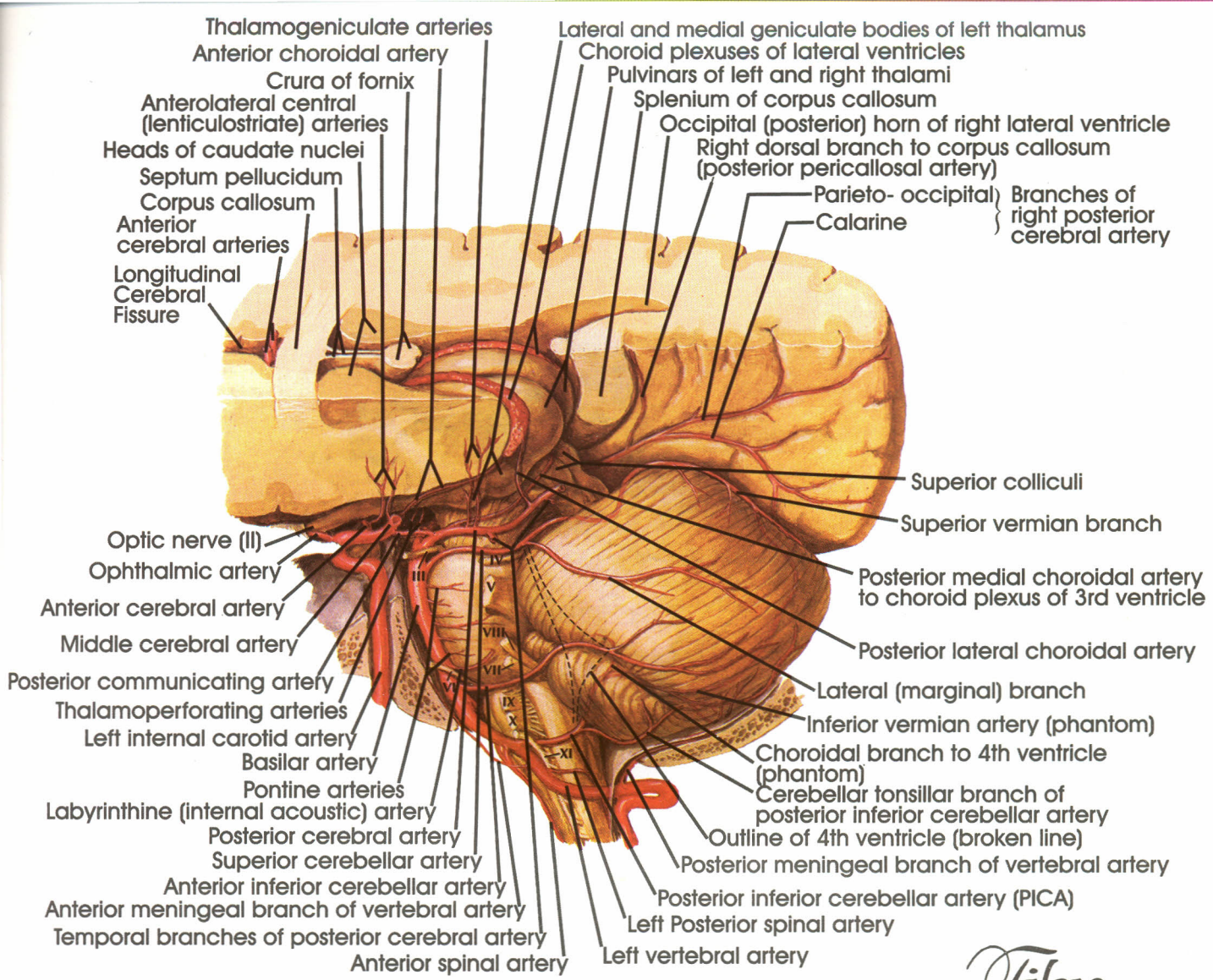


Spiky

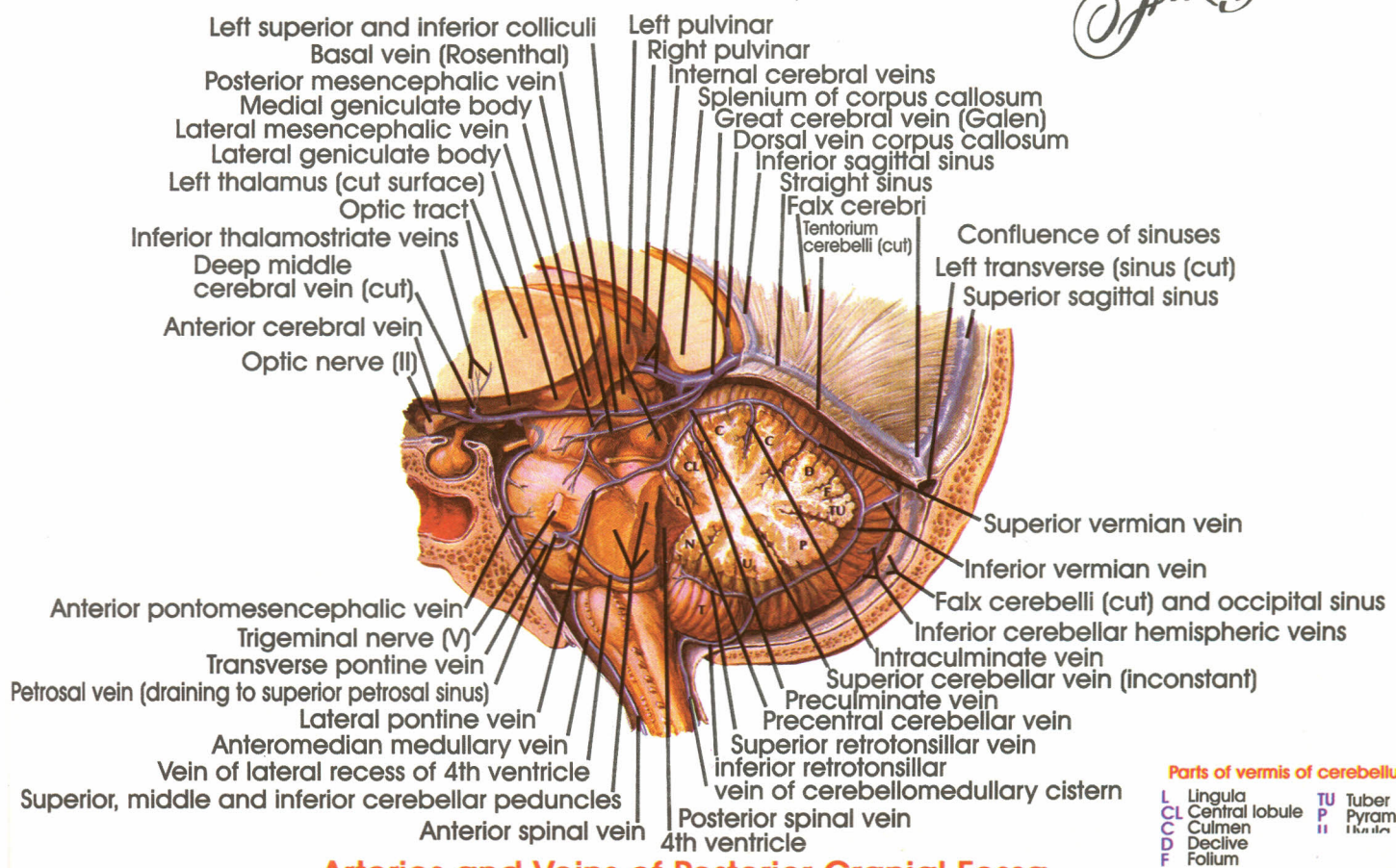
Deep veins of Brain



Subependymal veins of brain

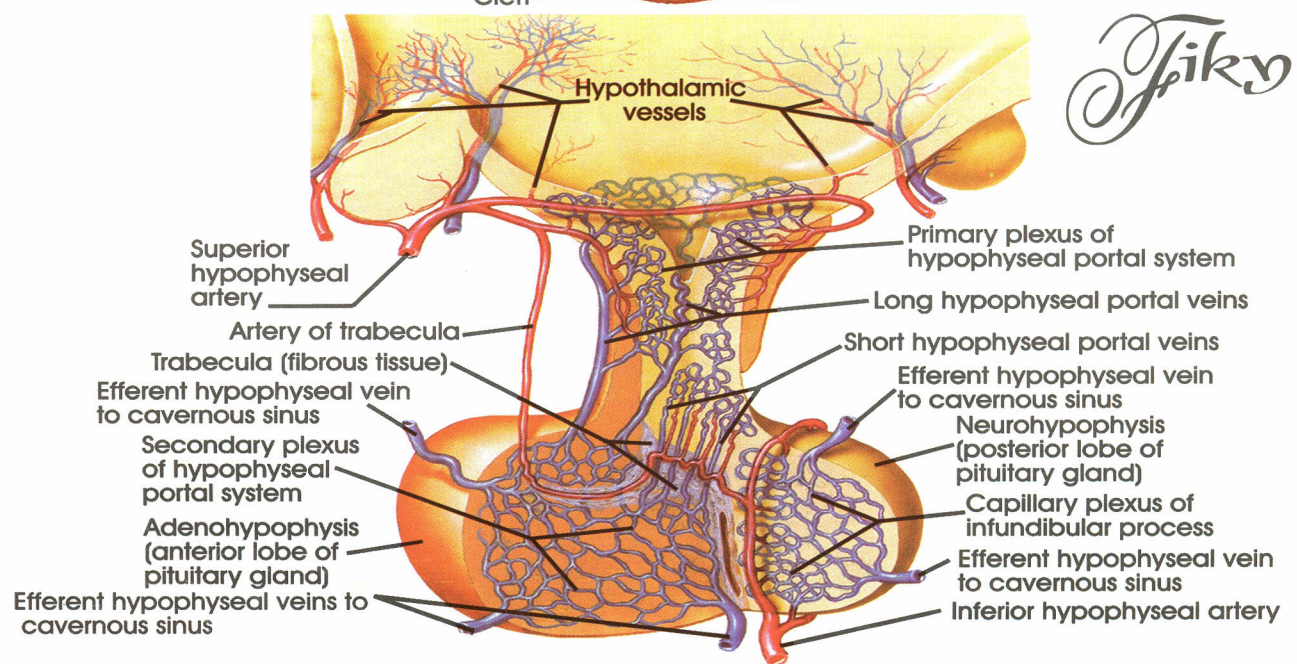
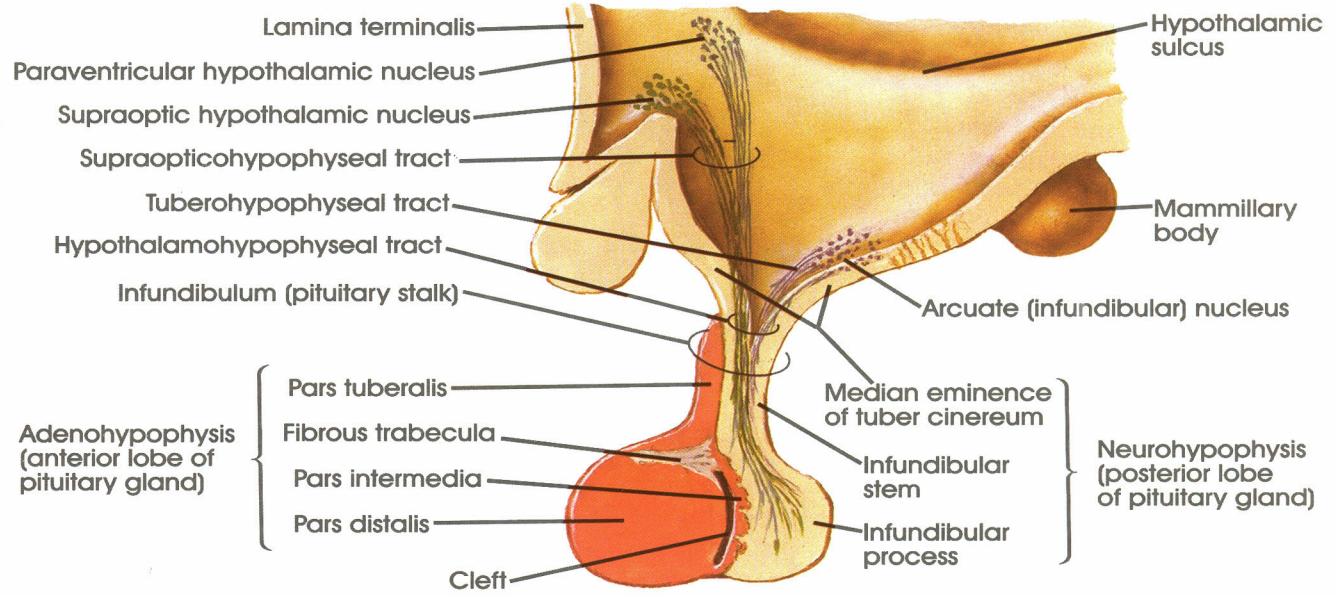
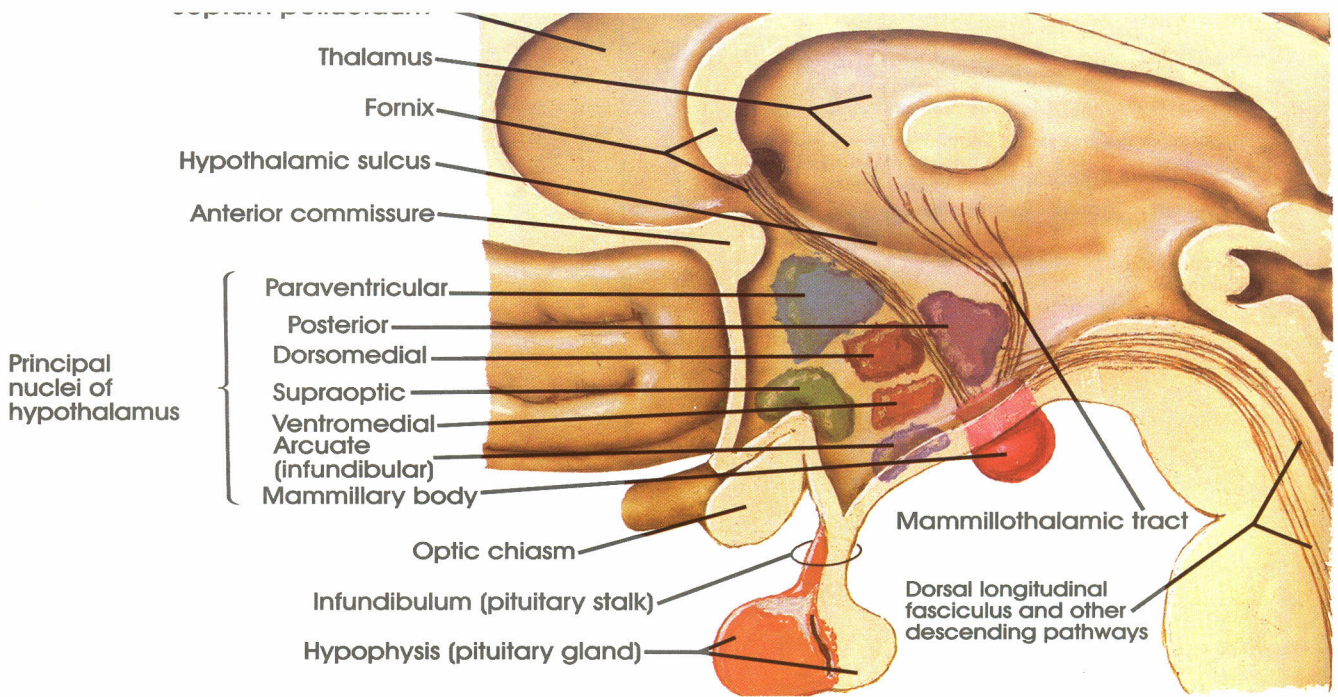


El-Fiky



Parts of vermis of cerebellum
 L Lingula
 C Central lobule
 CU Culmen
 P Declive
 F Follium
 TU Tuber
 P Pyramid
 II lobule

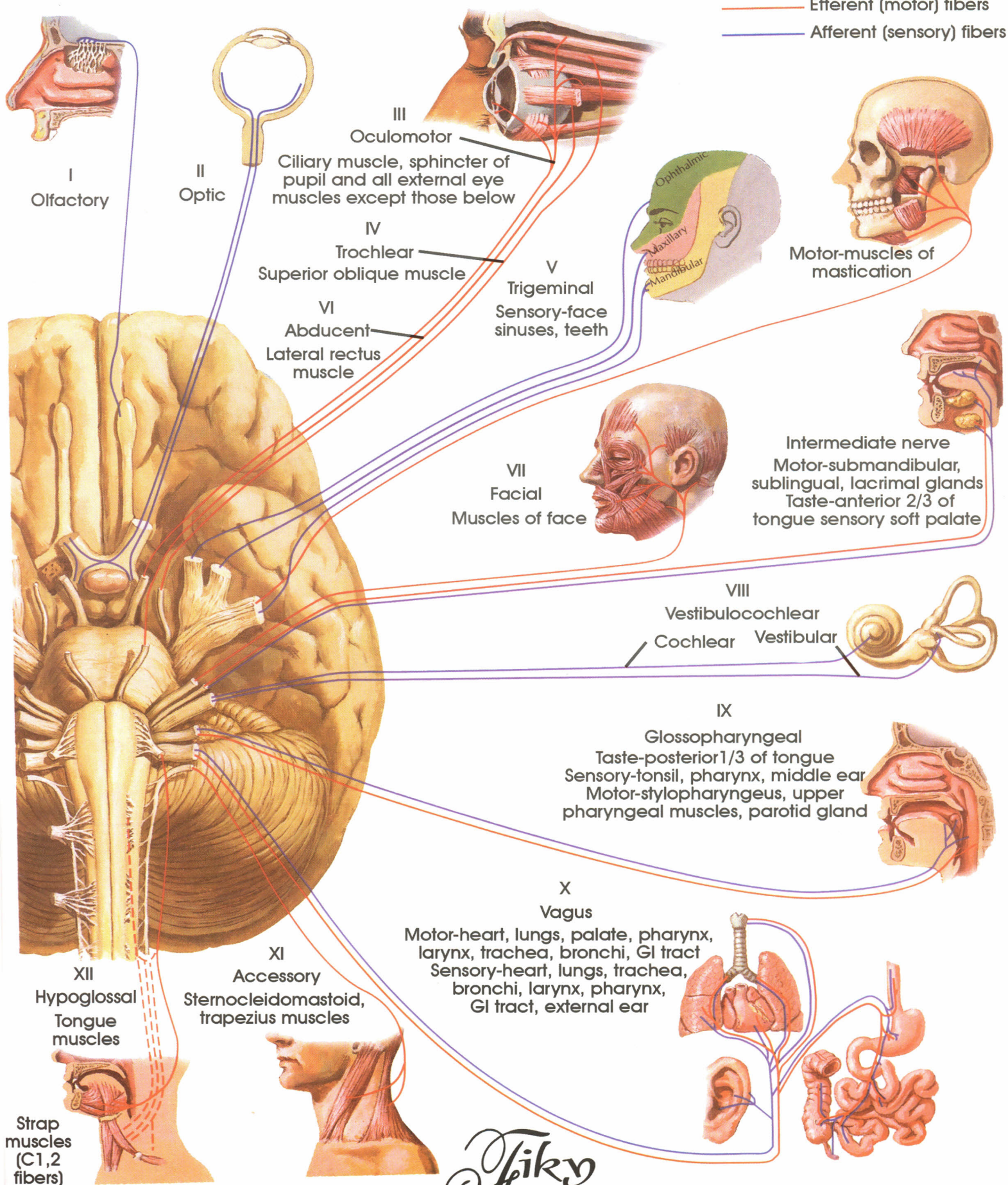
Arteries and Veins of Posterior Cranial Fossa



Fiky

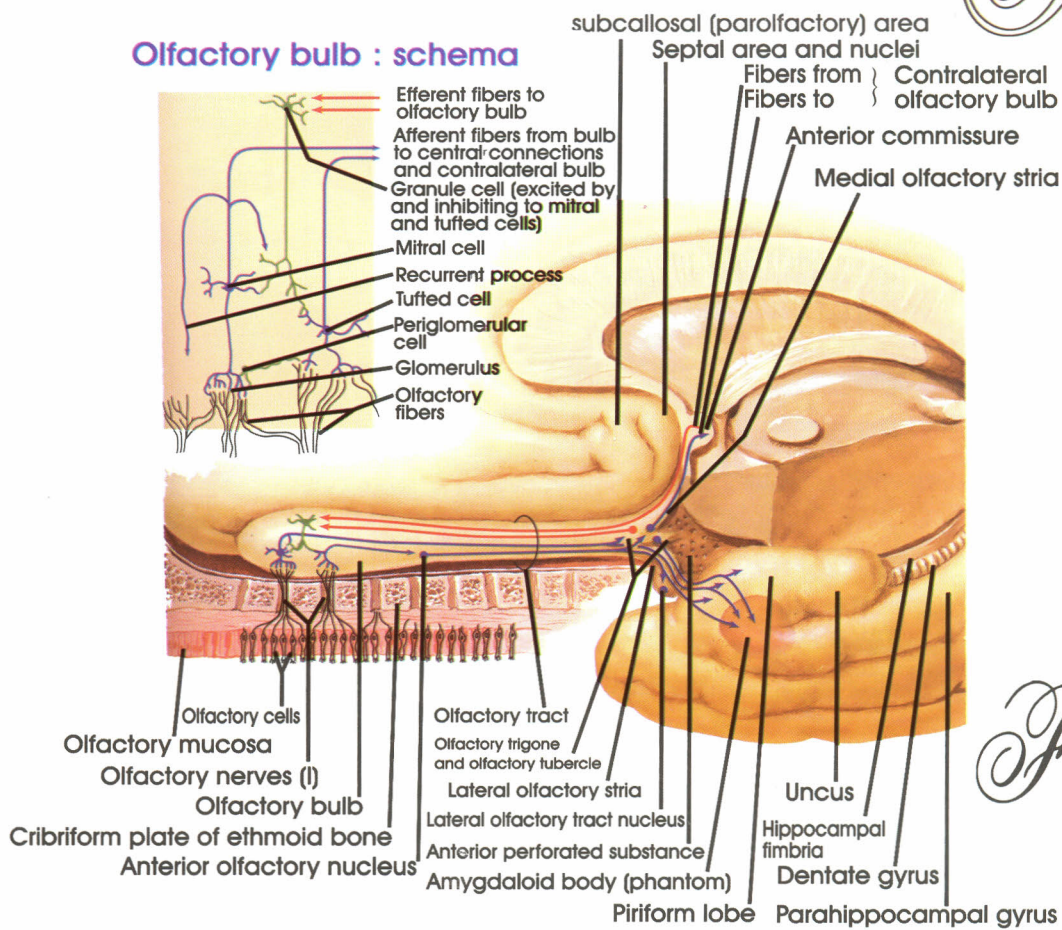
Hypothalamus and Pituitary Gland

- - - Spinal nerve fibers
 — Efferent (motor) fibers
 — Afferent (sensory) fibers



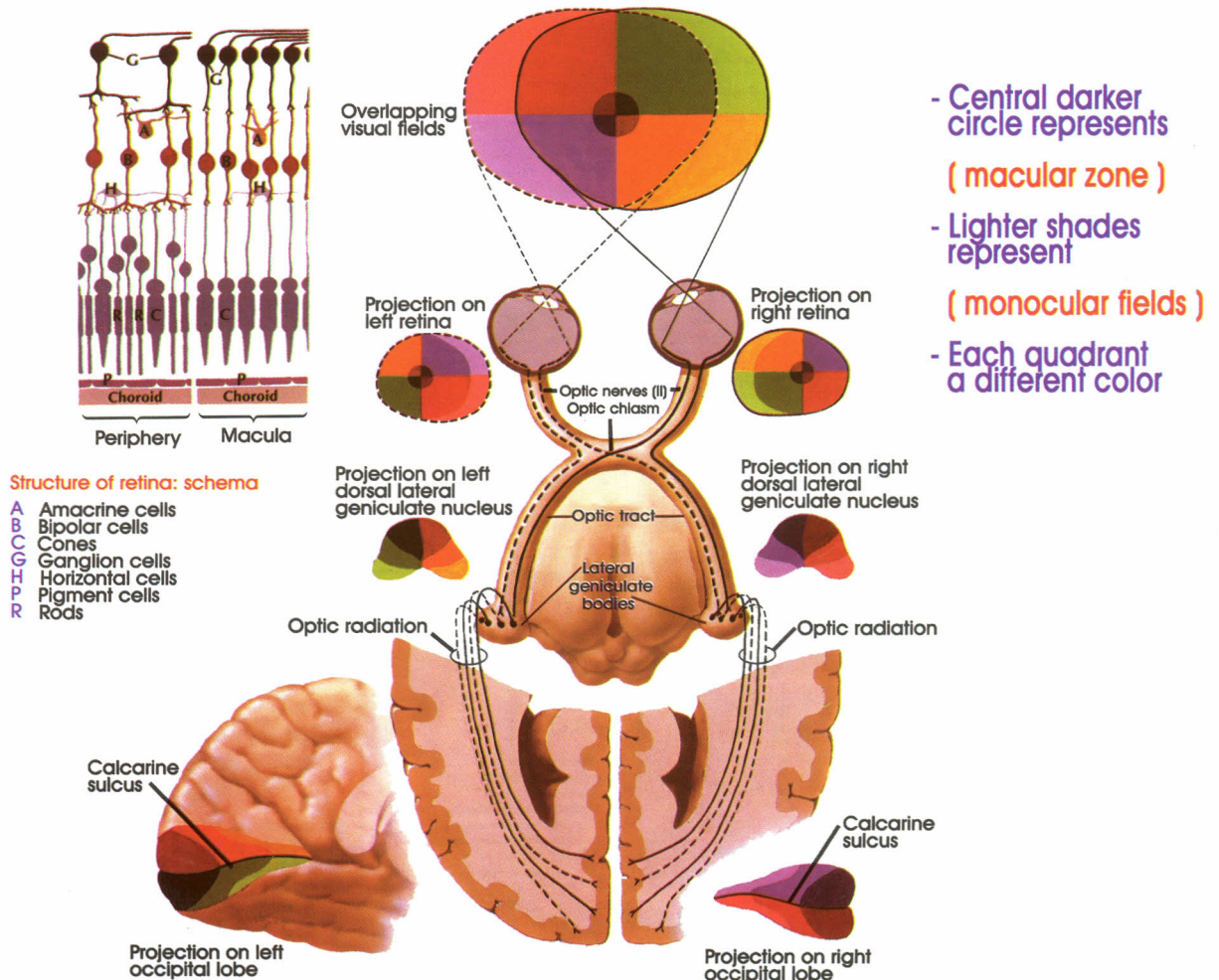
Cranial Nerves (Motor and Sensory distribution): schema

Olfactory bulb : schema

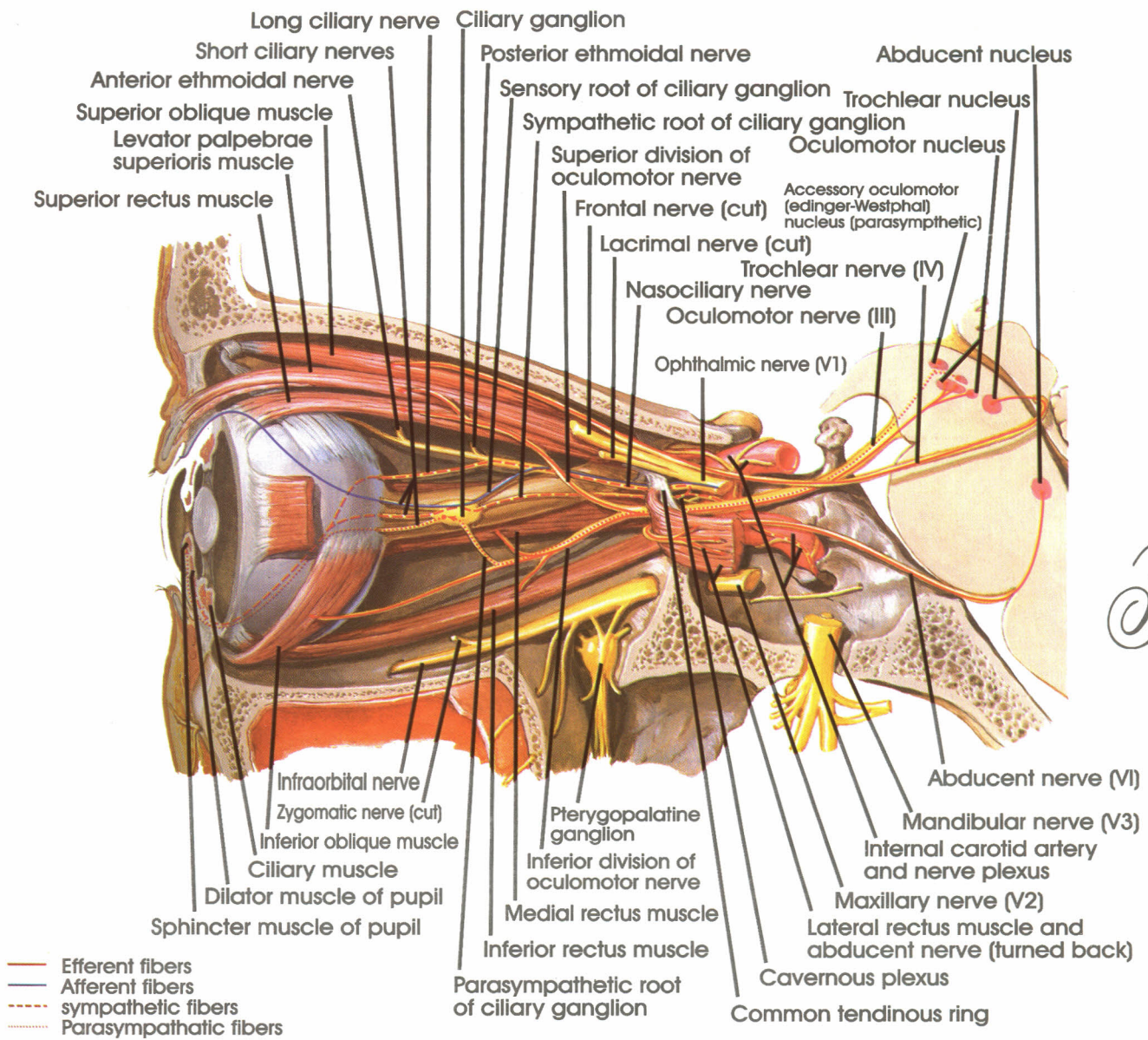


Fiky

Olfactory bulb cells: schema

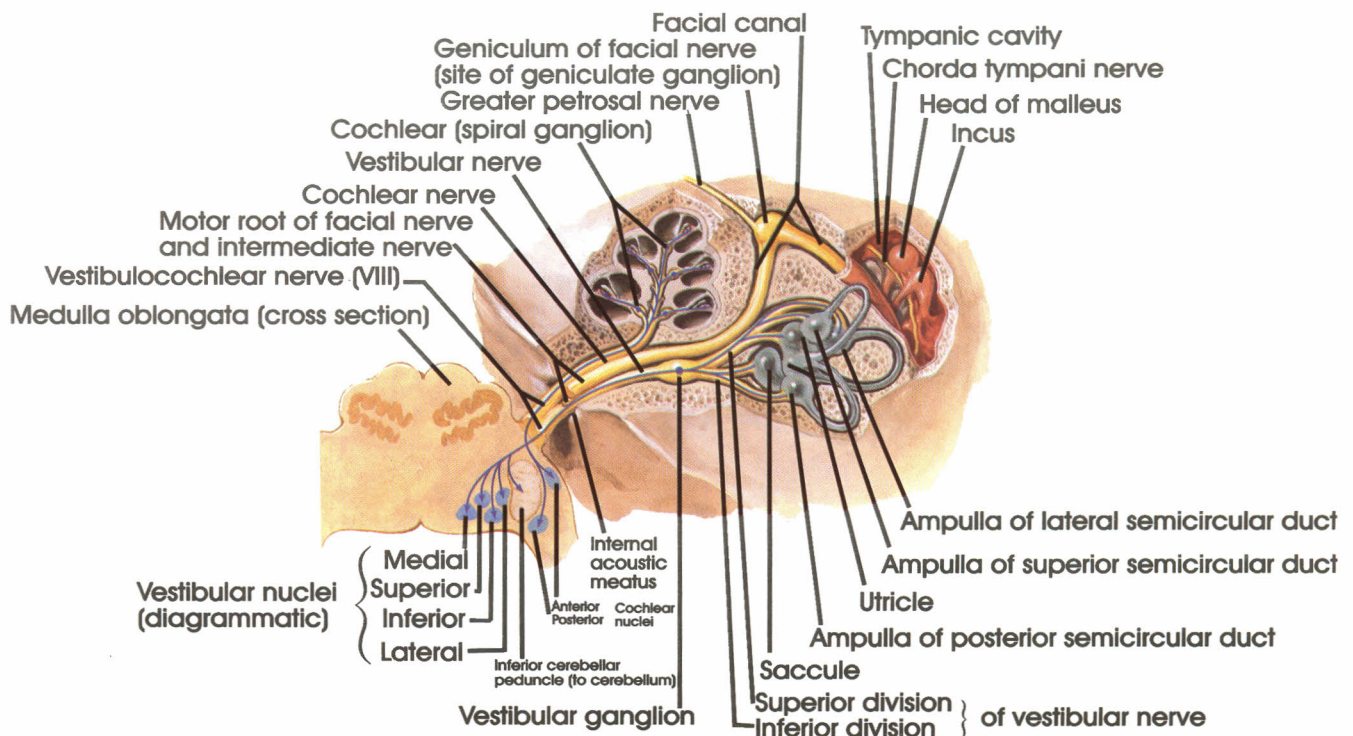


Optic Nerve (II) and Visual pathway Schema

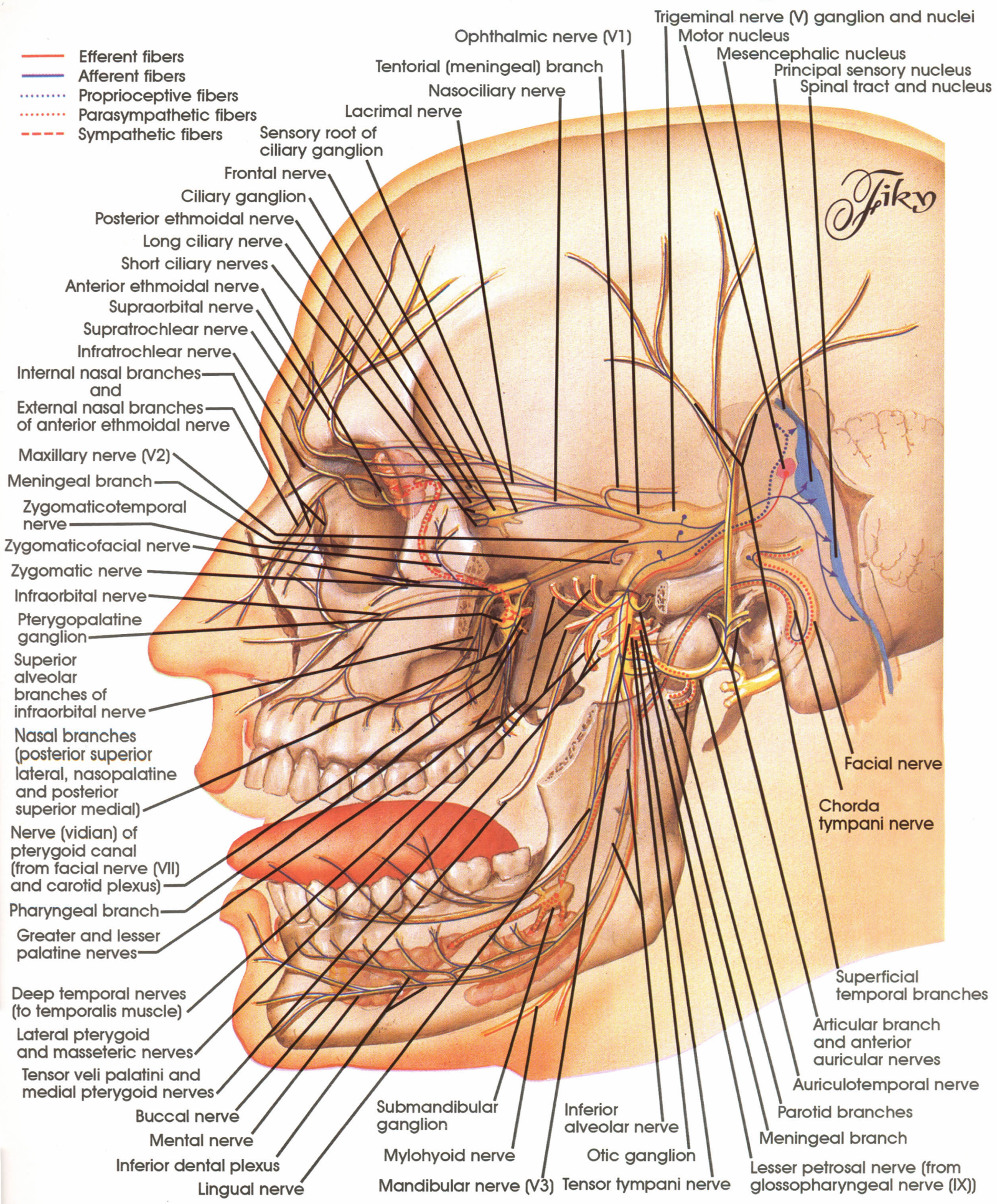


Fiky

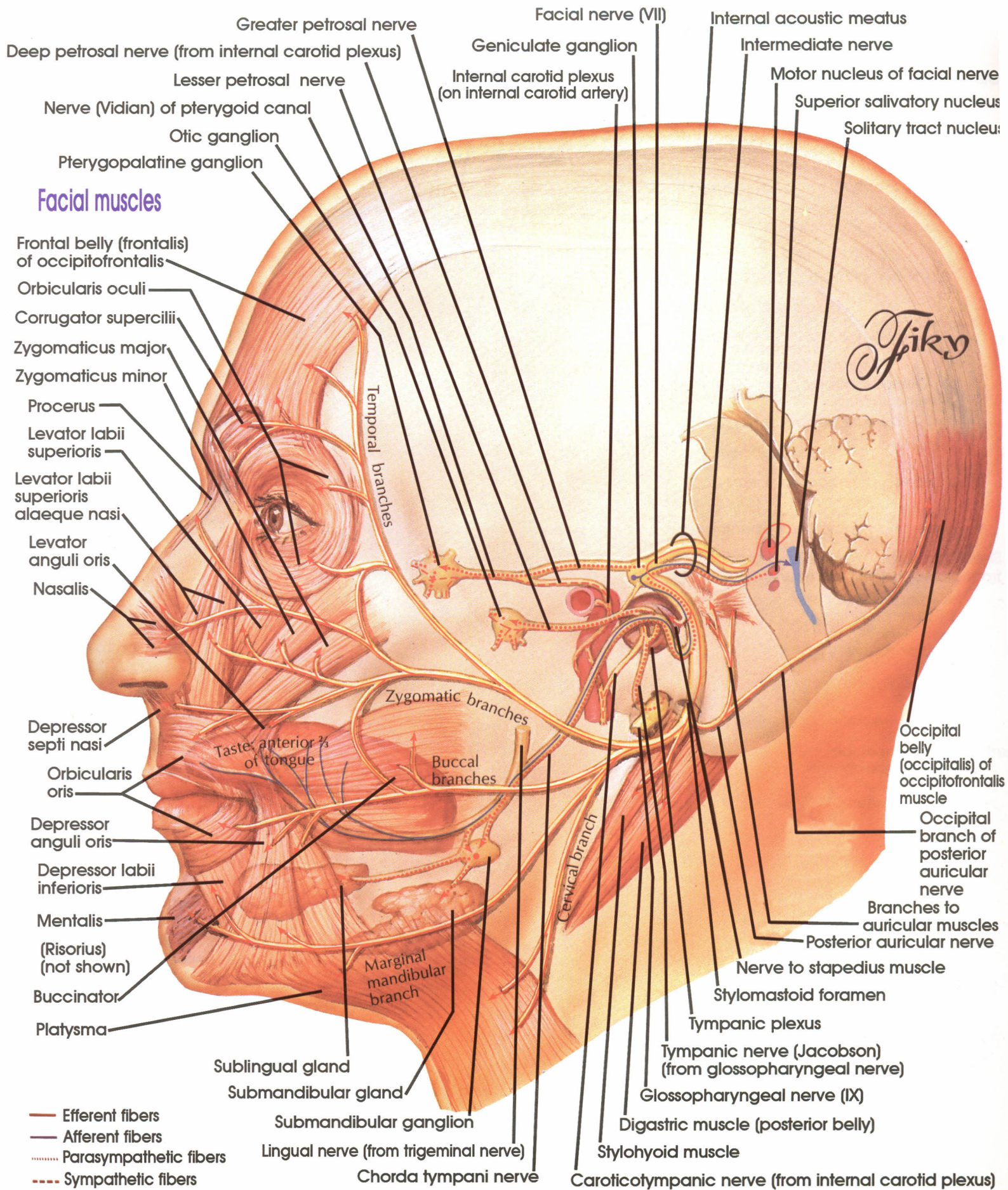
Oculomotor (III), Trochlear (IV) and Abducent (VI) Nerves: Schema



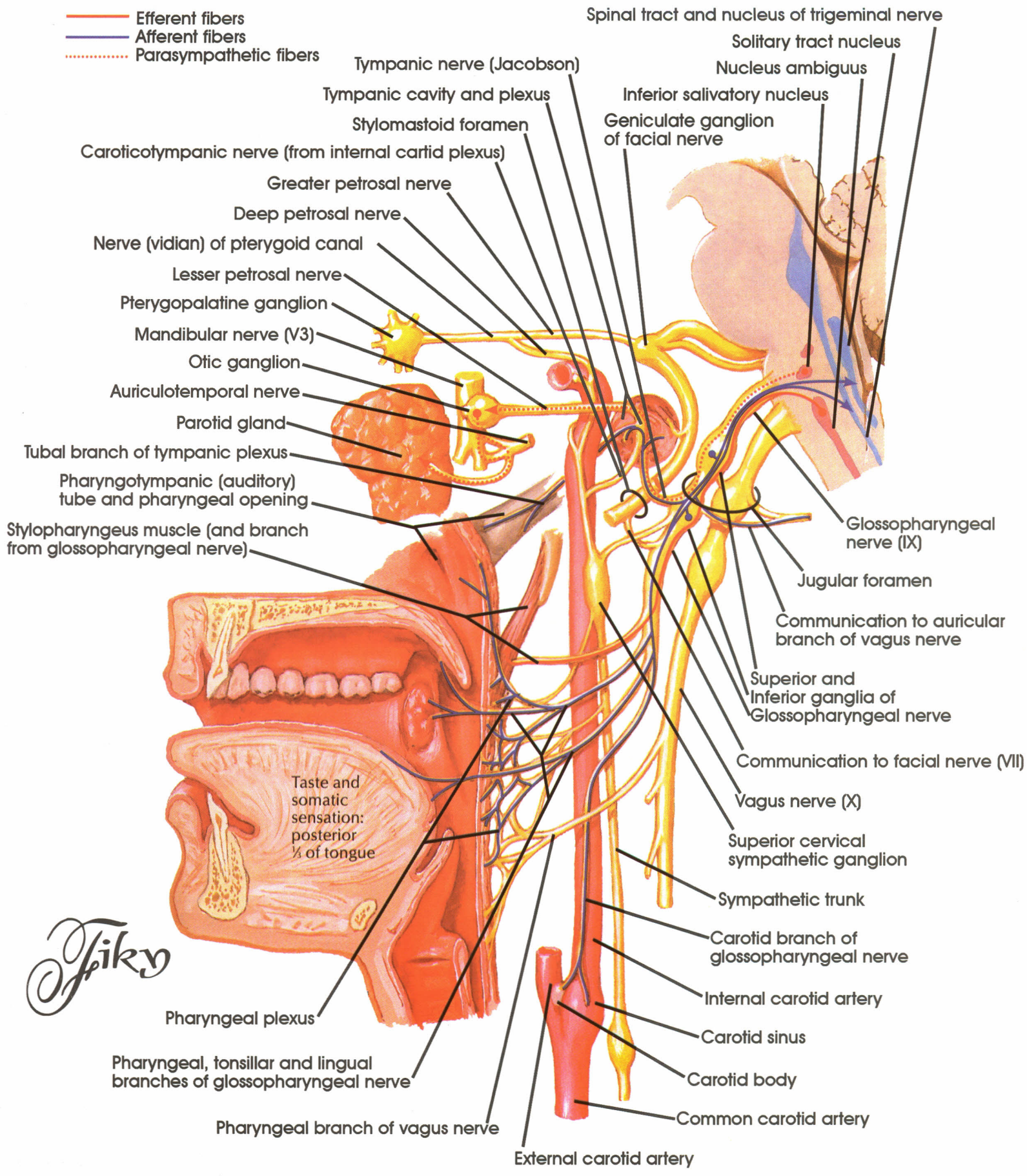
Vestibulocochlear Nerve (VIII): Schema



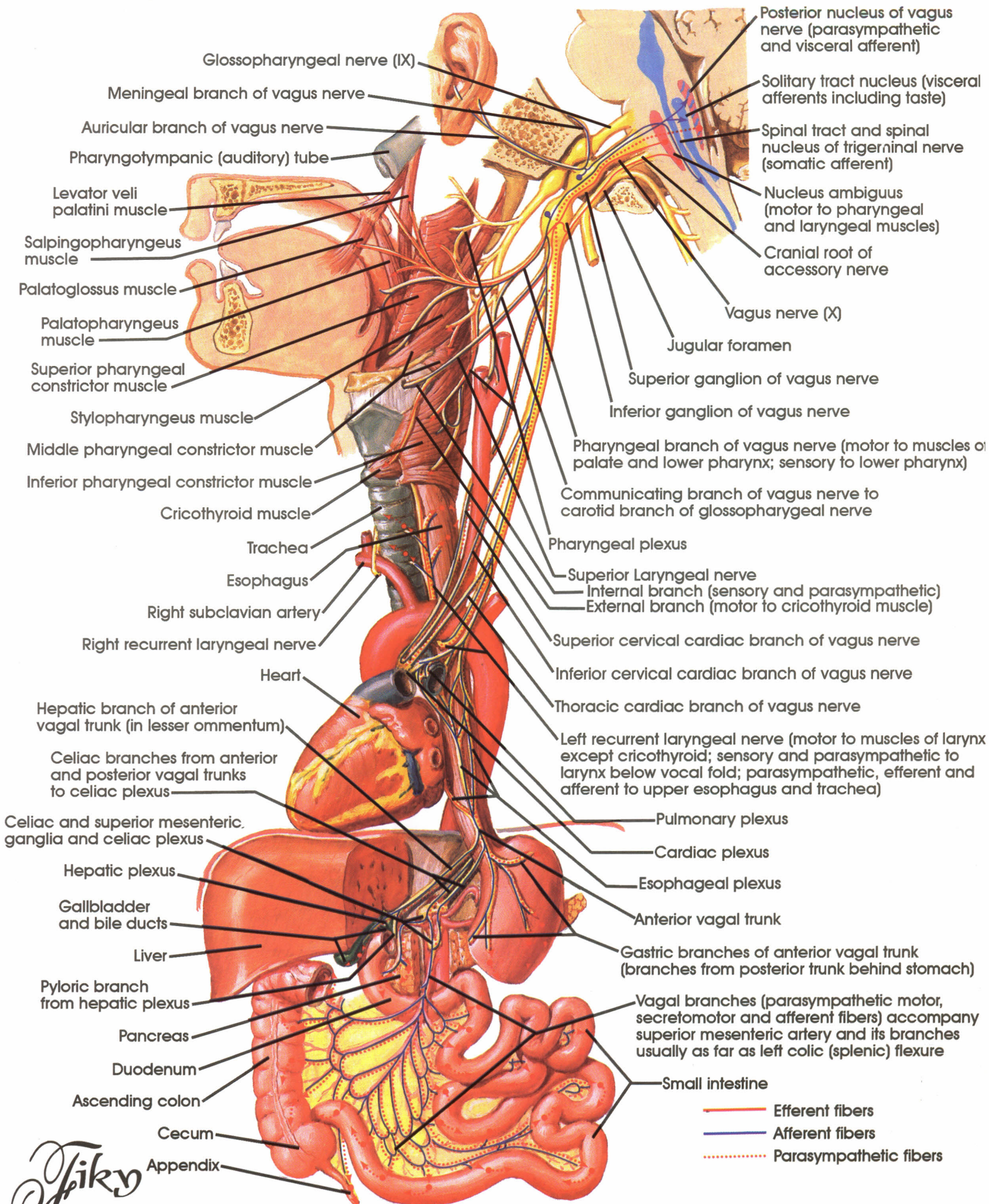
Trigeminal Nerve (V): Schema



Facial Nerve (VII): Schema

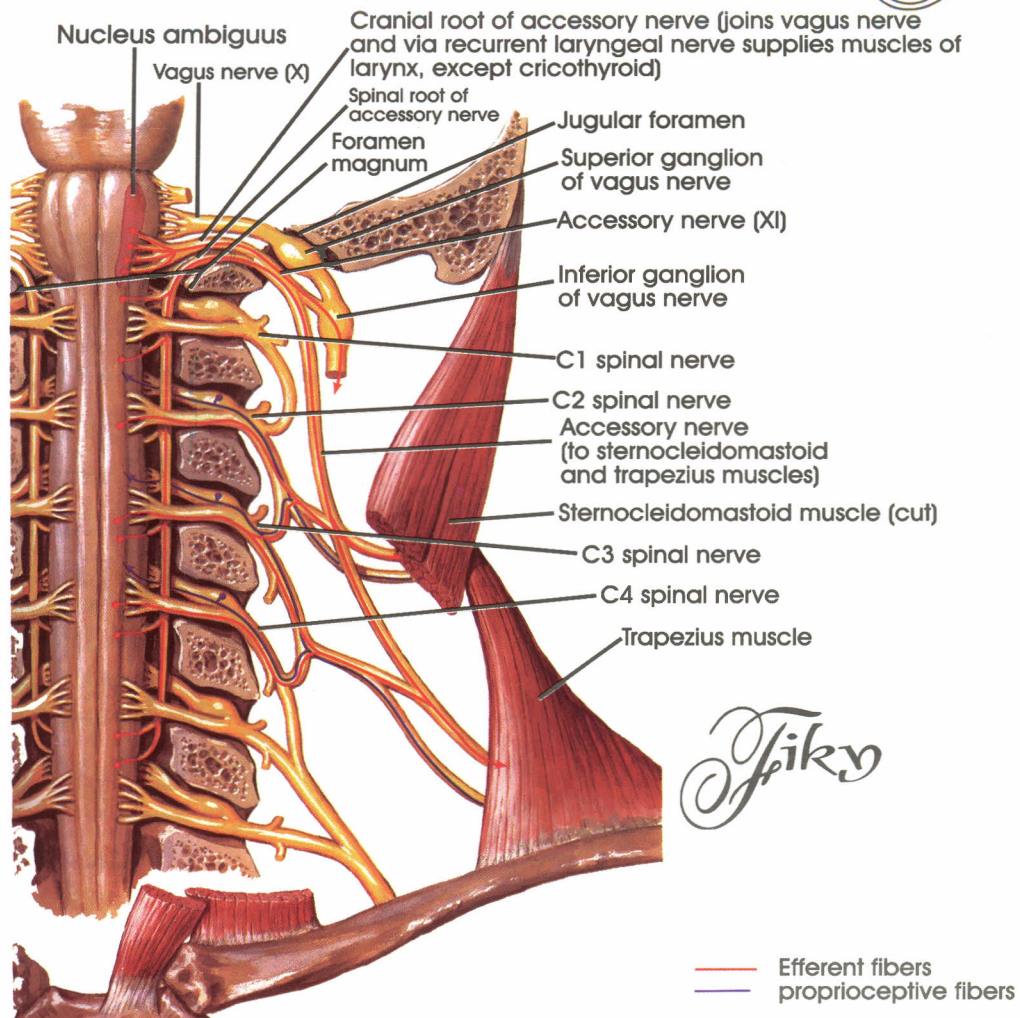


Glossopharyngeal Nerve (IX): Schema



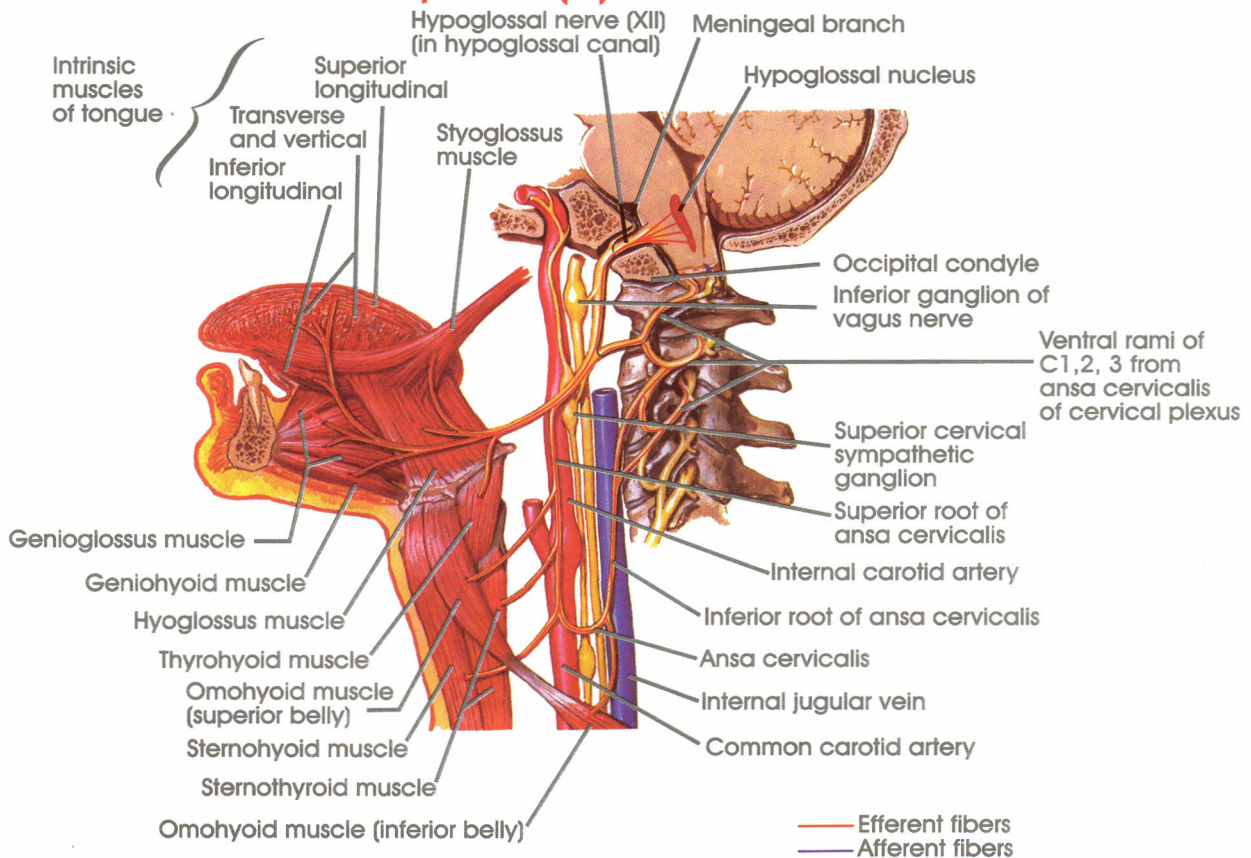
Vagus Nerve (X): Schema

El-Fiky

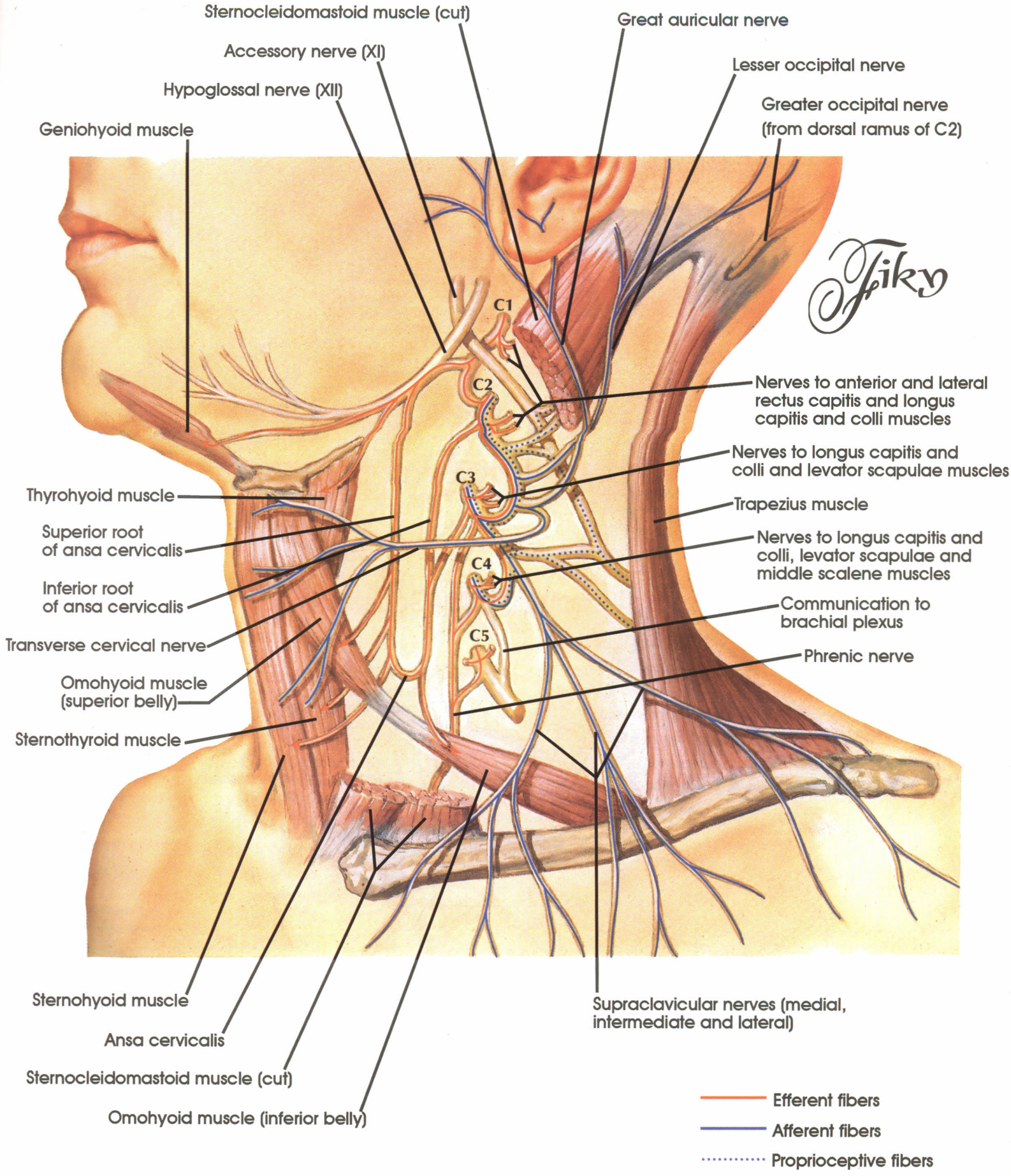


Fiky

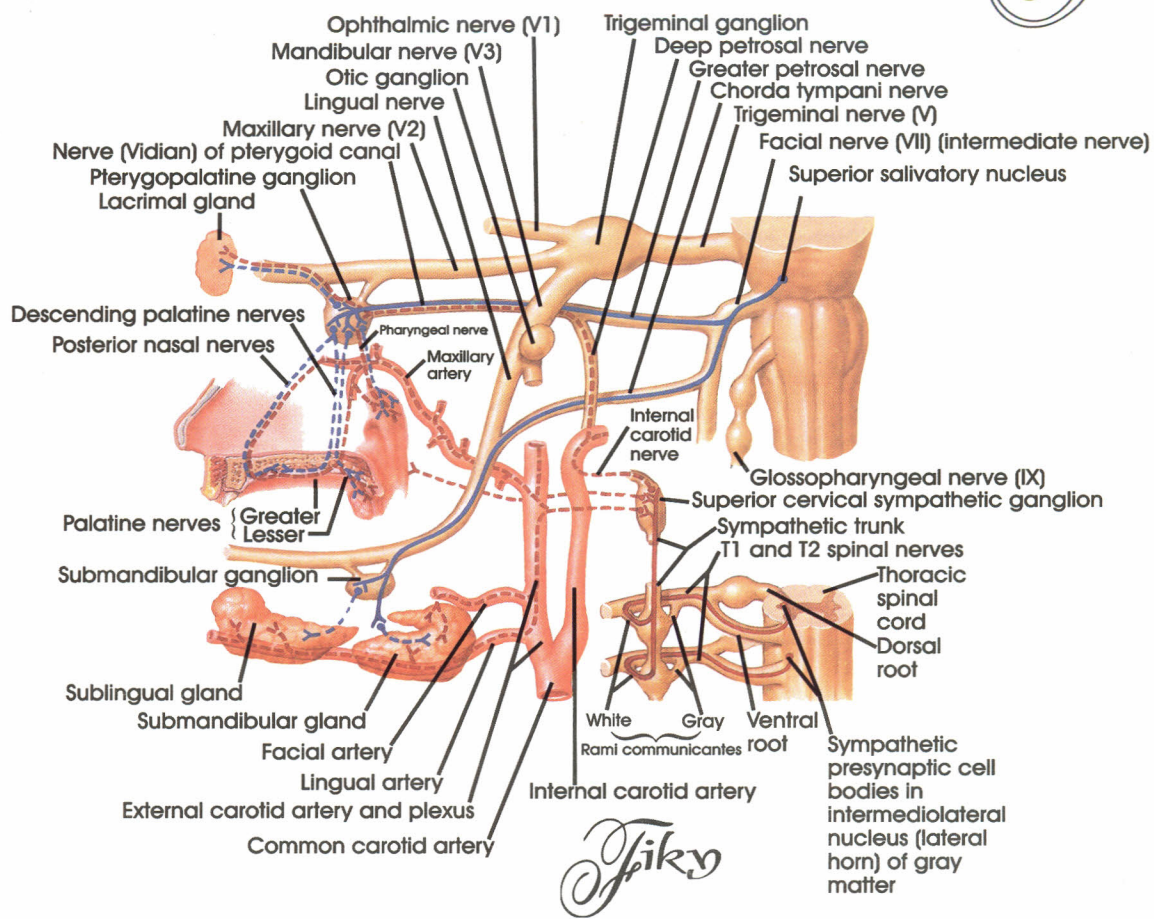
Accessory Nerve (XI): Schema



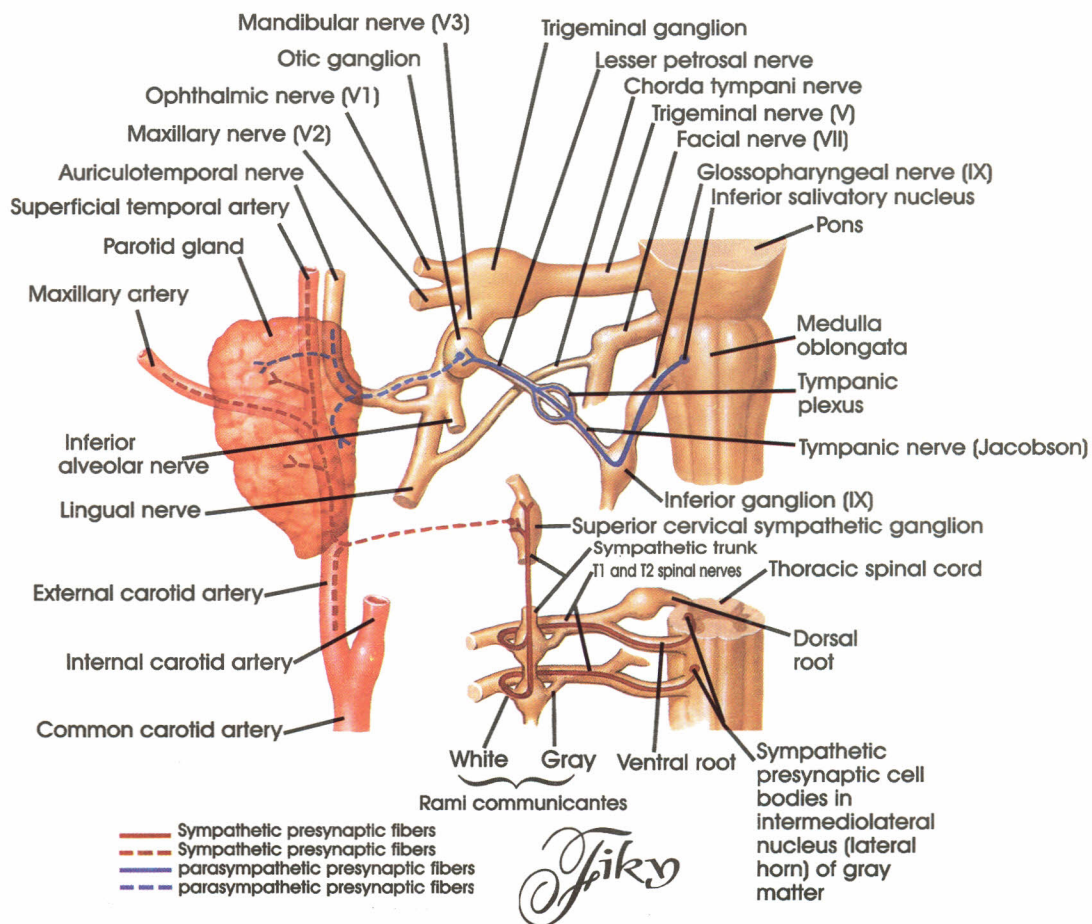
Hypoglossal Nerve (XII): Schema



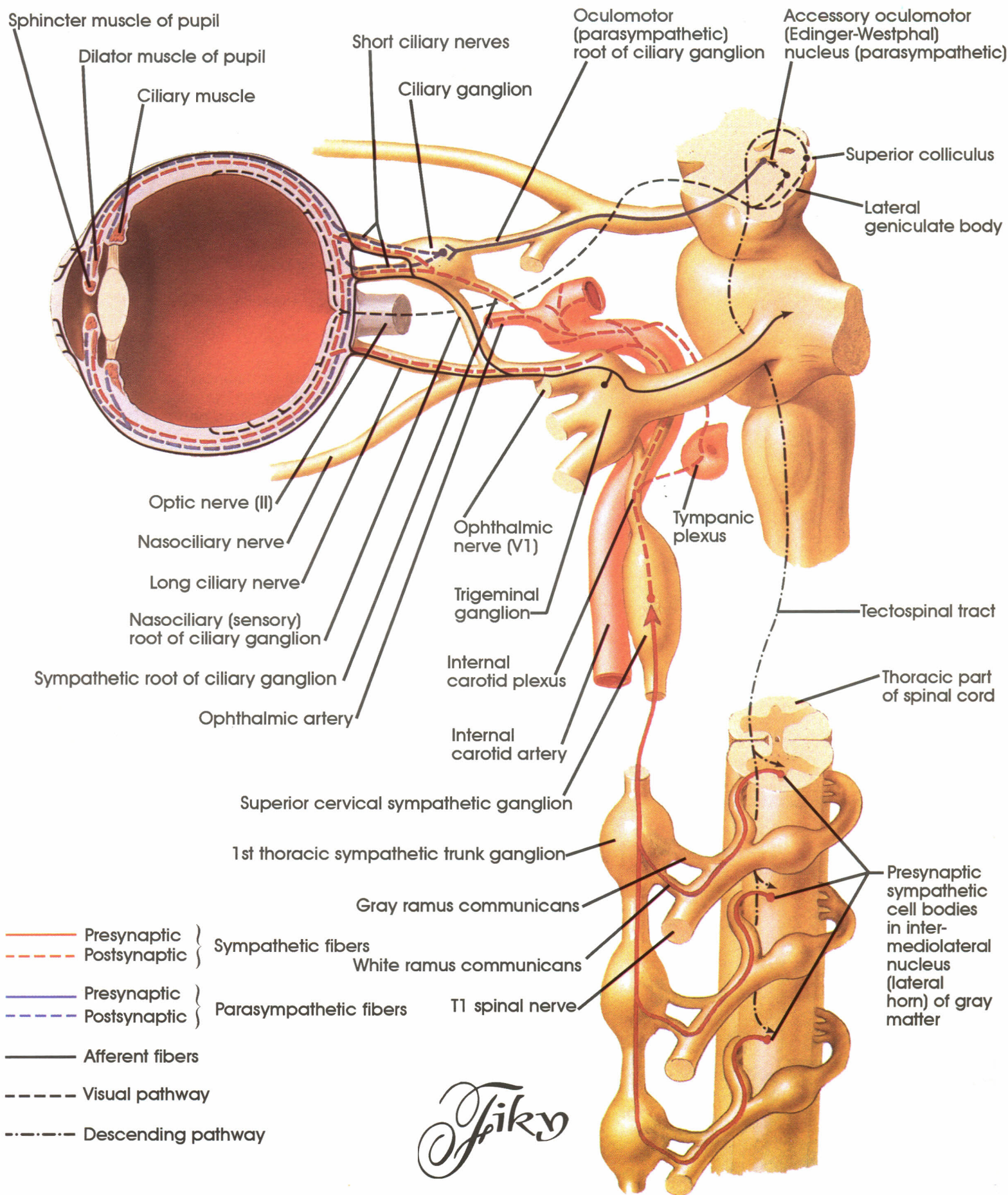
Cervical Plexus: Schema



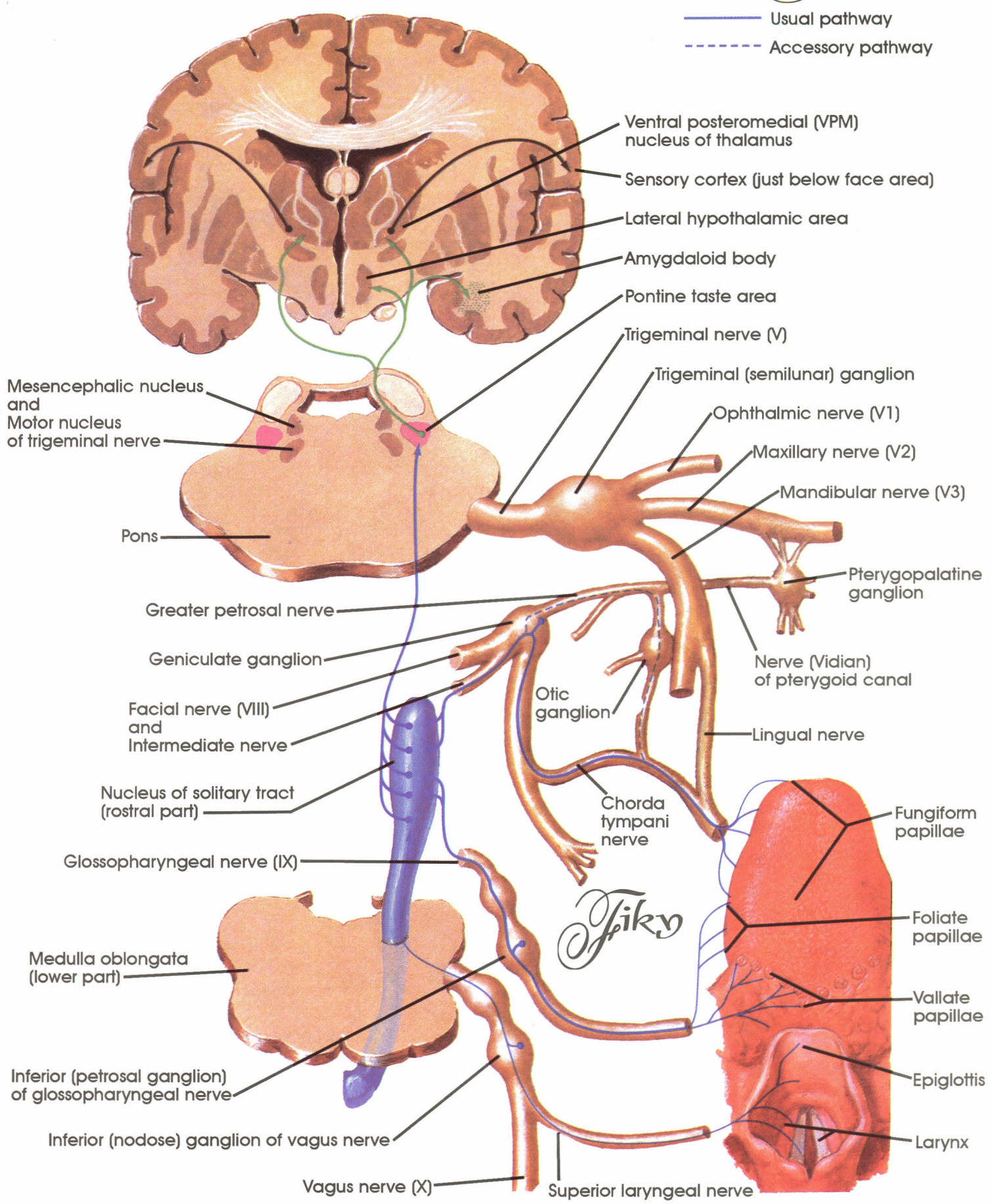
Pterygopalatine and submandibular Ganglia: Schema



Otic Ganglion: Schema

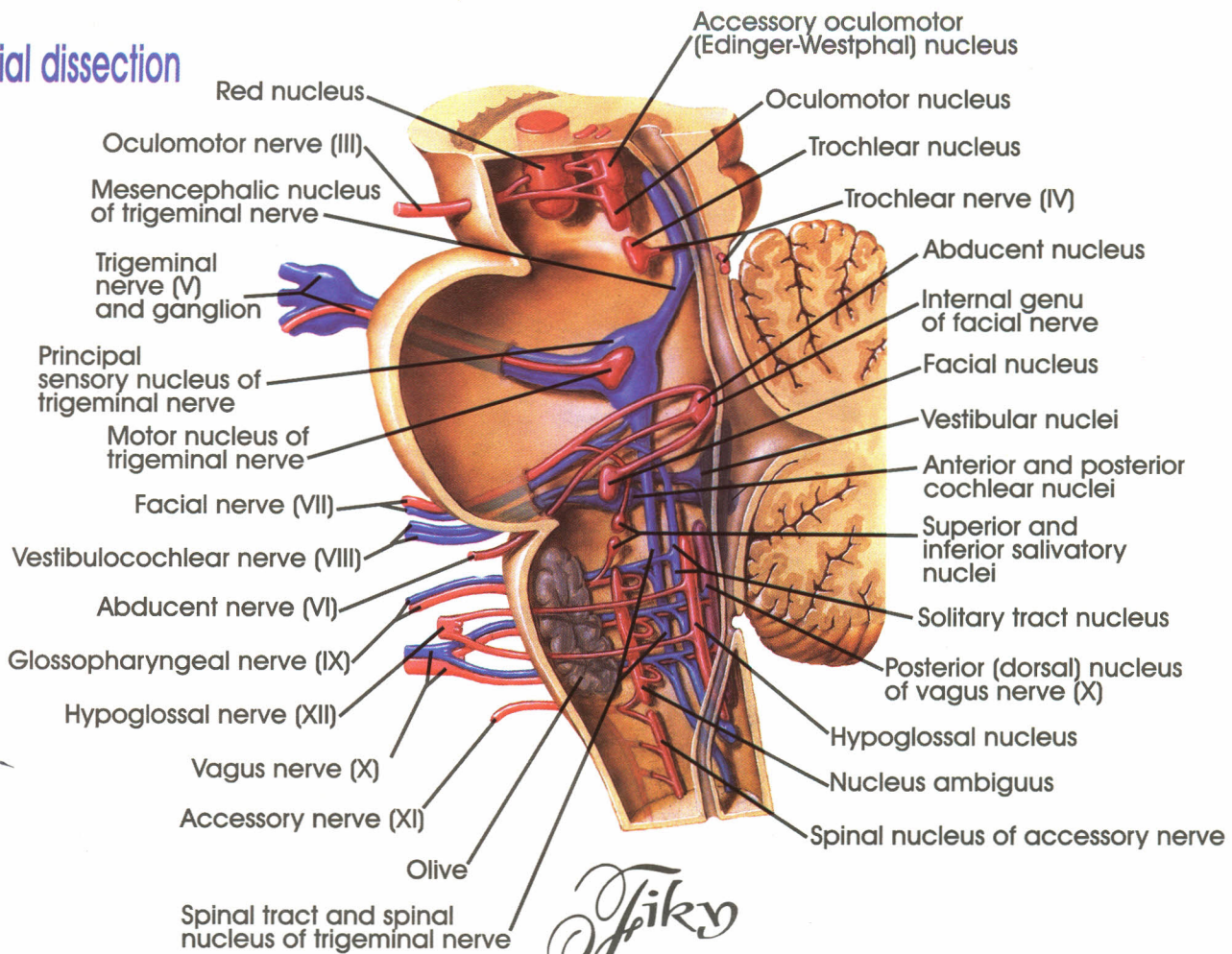


Ciliary Ganglion - Schema

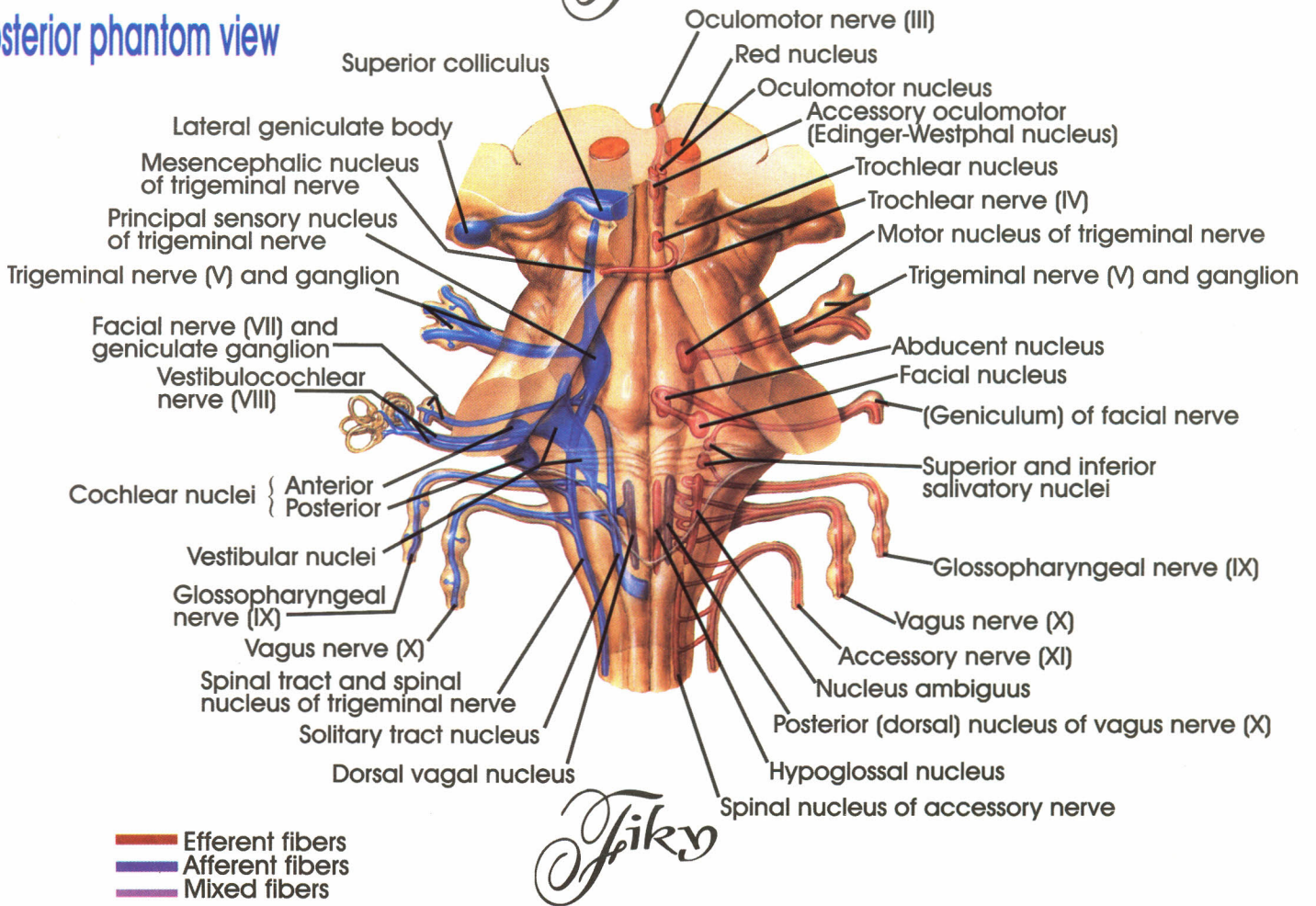


Taste Pathways: Schema

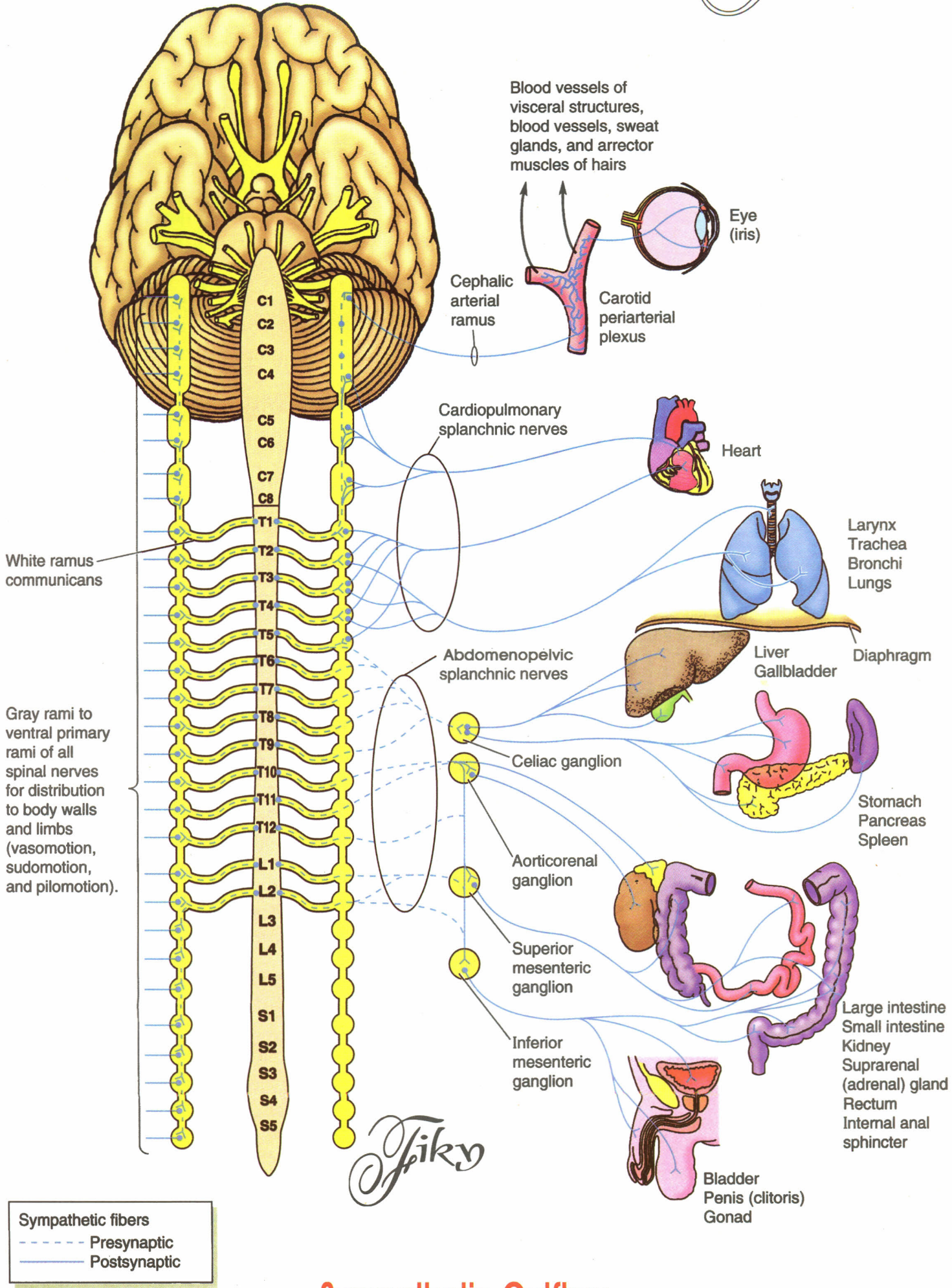
Medial dissection



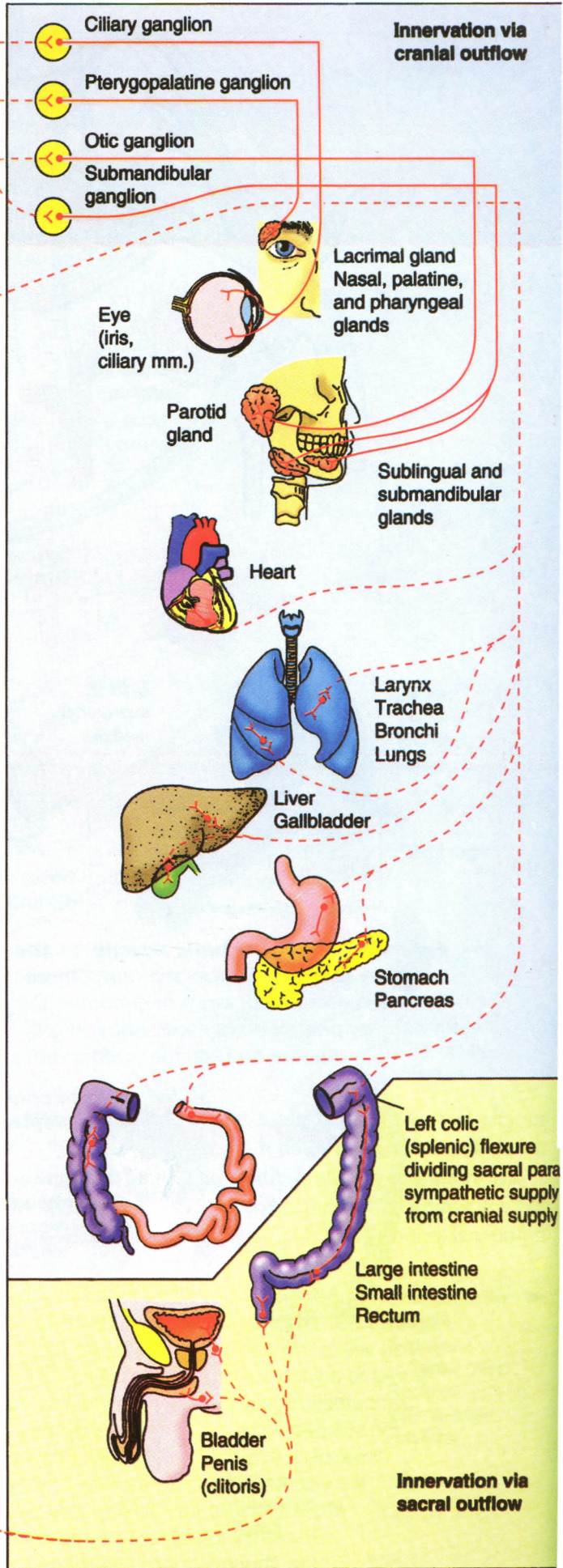
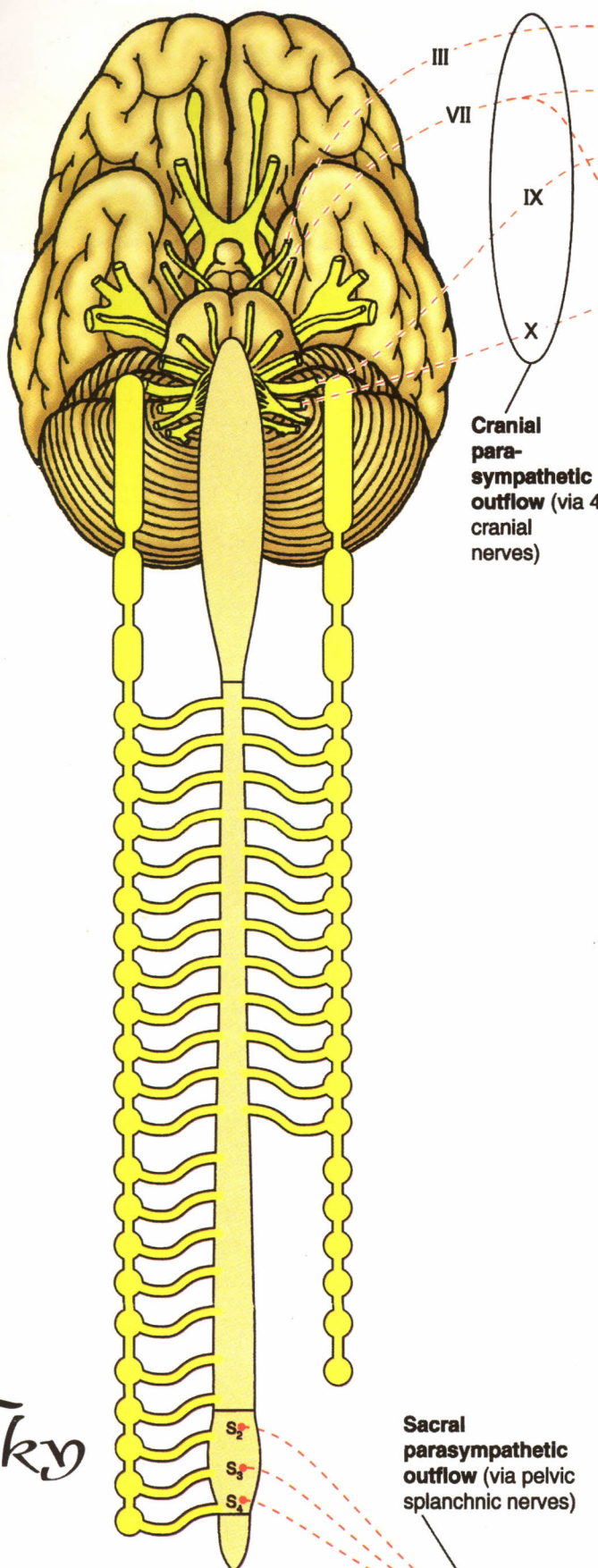
Posterior phantom view



Cranial Nerve Nuclei



Sympathetic Outflow



El-Fiky

Parasympathetic Outflow

El-Fiky's

MINI ATLAS OF
ANATOMY



FIKY'S MINI ATLAS:

- 1- Part I thorax & vertebral column.
- 2- Part II abdomen , pelvis & perineum.
- 3- Part III upper limb.
- 4- Part IV lower limb.
- 5- Part V head and neck.
- 6- Part VI neuroanatomy.

DR. MOHAMED EL-FIKY

Ass. Prof. of Anatomy & embryology
Faculty of Medicine Menoufia University

E.mail: dr_fiky@yahoo.com

Tel: (002) 0100 6662266

